JOURNAL OF CLINICAL MEDICINE OF KAZAKHSTAN (E-ISSN 2313-1519)
Original article DOI: https://doi.org/10.23950/jcmk/10800

Subadventitial dismembered pyeloureteroplasty – new surgical technique for correction of uretero-pelvic junction stenosis

Akif Memmed oglu Bağirov
Department of Urology, Azerbaijan Medical University, Azerbaijan

Received: 2021-01-22.
Accepted: 2021-03-10

J Clin Med Kaz 2021; 18(1):53-56

Corresponding author:
Akif Memmed oglu Bağirov.
E-mail: dr.akif.bagirov@gmail.com

Abstract

Introduction: Open or laparoscopic dismembered pyeloplasty has been the gold standard for the correction of ureteropelvic junction obstruction (UPJO) with a success rate of about 90%. Main insufficient feature of dismembered pyeloureteroplasty is interfering ureteral blood supply, which creates the prerequisites for the deterioration of the regeneration of the ureter and the possibility of developing restenosis.

Material and methods: We offered and applied the new method – subadventitial resection of ureteropelvic junction (UPJ) to prevent damage to vessels of the distal part of pelvis and proximal part of the ureter. The protection of blood supply in this area should improve anastomosis regeneration and prevent fibrotic changes for long time, simultaneously providing better condition for the kinetic ability of the ureter.

Results: Retrospective analysis of 106 patients with hydronephrosis, whom performed 108 open dismembered pyeloplasty (two patients were operated bilaterally) with subadventitial resection of UPJ from 1998-2020 years with a mean follow-up of 36 month shows that this technique has advantages over analogues.

Conclusion: Our 22 years of experience shows that the technique of subadventitial resection of the ureter, allows us to save the ureteral blood circulation and thus creates conditions for better regeneration of the anastomosis and prevent later complications of dismembered pyelouretereroplasty.

Key words: uretero-pelvic stenosis, dismembered pyelouretero-plasty, subadventitial resection of the ureter.

Introduction

Hydronephrosis due to stenosis of the UPJ is most common congenital abnormality of upper urinary tract and one of the main reasons for the gradual impairment of kidney function on the corresponding side, particularly in children and young adults.

Improvement in diagnostic methods and widespread application ultrasonography in prenatal and antenatal periods allows early detection and early surgical treatment to prevent destructive changes in the hydronephrotic kidneys.

Progressive deterioration of ipsilateral renal function or impairment of overall renal function and symptoms related to the complications of the UPJO - such as: infection, secondary kidney stones, occasionally nephrogenic hypertension are indications to the surgical treatments. Although the need for surgical treatment for UPJO is not in doubt, ways to correct the restoration of patency of the pelvioureteral segment are still discussed.

Today, relatively new minimally invasive methods, such as balloon dilatation, ureterorenoscopic endopyelotomy, percutaneous pyeloplasty (endopyelotomy) has been introduced into clinical practice, but dismembered ureteropyeloplasty remain the gold standard for the treatment of hydronephrosis [1]. Despite the fact that the effectiveness of this method of pyeloplasty is universally recognized, resolution of hydronephrosis is observed in about 90% of cases, about 9% of patients may need reoperation, up to nephrectomy. As a cause of a negative result, restenosis of

the ureteropelvic junction is usually detected [2,3].

The blood supply to the ureteropelvic junction and the proximal part of the ureter is mainly provided by the branch of the renal artery, which supplies the renal pelvis with blood and continues through the adventitial tissue of the ureter [4]. Dismembered pyeloureteroplasty is accompanied by resection of the ureteral artery, which leads to a deterioration in the blood supply to the ureter [5].

Dissection and resection of the ureter without damaging the ureteral artery can create opportunities for adequate regeneration, which is one of the initial principles of any plastic surgery. Considering that the ureteric artery is located in the adventitial layer, we developed new method for dismembered pieloureteroplasty - subadventitial dissection and resection of the ureter. This method allowed the preservation of blood supply to the resected ureter, and thereby created the conditions for better regeneration, as well as the prevention of restenosis.

In this article, we discuss the results of our 22 years of experience in the treatment of patients with renal hydronephrosis, operated according to the technique of subadventitial resection of the ureteropelvic junction with open dismembered pyeloureteroplasty by Anderson-Hynes.

Material and methods

From march 1998, through march 2020 - 108 consecutive open dismembered pyeloureteroplasties by Anderson-Hynes were performed in 106 patients with application of the new surgical technique – subadventitial resection of the UPJ (in one patient for hydronephrosis of solitary kidney, bilateral in two cases: in single session - in one case, in two stages – in one case). All patients were operated on by the same surgeon (by author).

Clinical manifestations as periodic pains in the lumbar region were observed in half of the patients (55 patients), in one patient (63 years old women) the examination was conducted for nephrogenic hypertension, in two infants hydronephrosis was detected during prenatal examination, in the remaining cases with ultrasound testing not related to this pathology. The average patient age was 18.4 years (range 1- 63 years).

Preoperative evaluation included urine analysis, urine culture when indicated, an ultrasonography, renal function tests. Preoperative renal function was studied using excretory urography in all patients. Diuretic renal scan (DRS) was applied in cases on suspicion to nonobstructed pyelocalicoectasy.

In postoperative period patients were observed from 6 month to 10 years (median 36 month). Patients with positive dynamics, regression of hydronephrosis and normal regeneration of the renal parenchyma were monitored on the basis of serum creatinine levels, urinalysis and ultrasound examination. If a relapse was suspected, excretory urography (in one case + retrograde pyelography) or CT urography was used.

23 patients underwent pyeloureteroplasty for grade II hydronephrosis, 83 patients for grade III hydronephrosis (including two bilateral), a horseshoe kidney was detected in one patient, and two patients were complicated by secondary kidney stones.

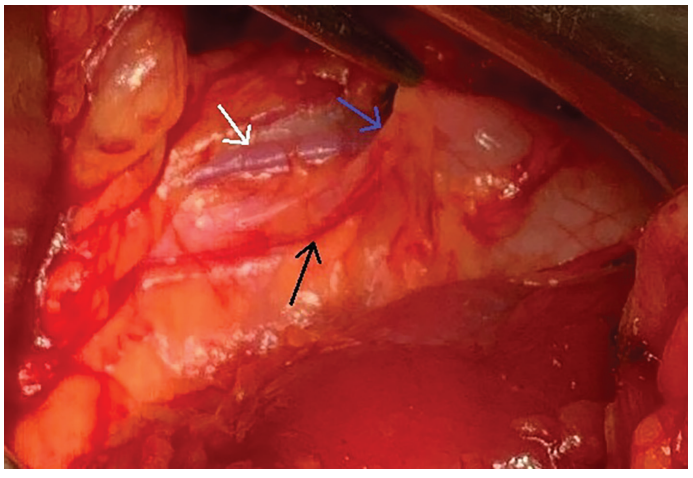

Figure 1. UPJ area in open dismembered ureteropyeloplasty. White arrow – testicular vein; blue arrow – ureter; black arrow – ureteral artery.

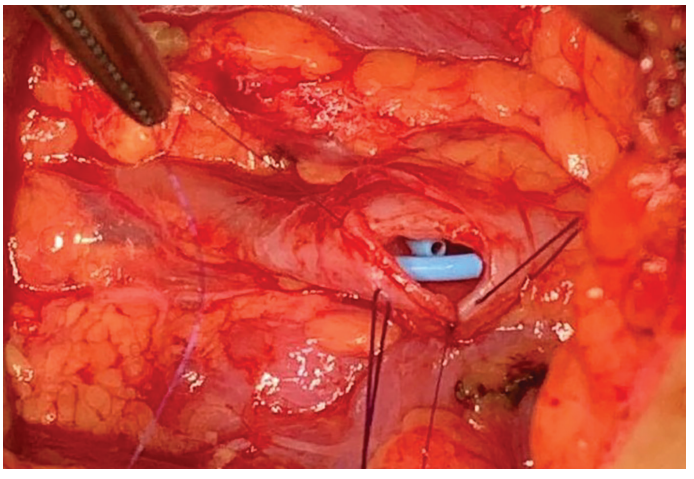

Figure 3. An anastomosis of the posterior wall between the ureter and renal pelvis.

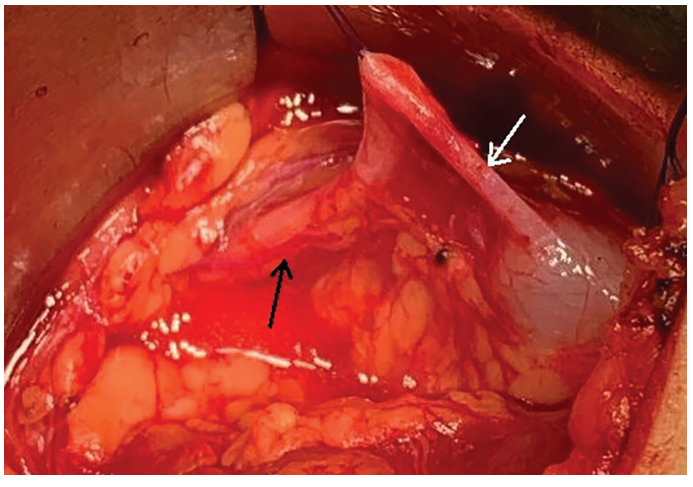

Figure 2. Incision and dissection adventitial layer. White arrow – ureter; black arrow – ureteral artery.

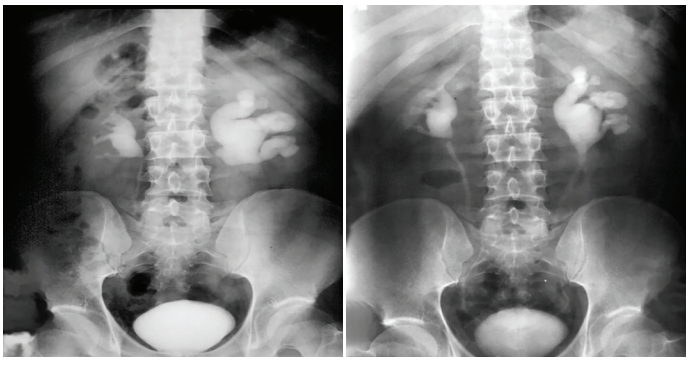

A B

Figure 3. A - Excretory urography - 120 minutes. Left-sided grade III hydronephrosis and right-sided pyeloectasis (grade I hydronephrosis) are revealed. B - Excretory urography - 30 minutes after 1 month subadventital pyeloureteroplasty. It is determined that the UPJ has a normal pass ability and a decrease in hydronephrosis.

Has been applied open pyeloureterplasty techniques with miniaturization of the incisions. Usually, anterior lumbotomy was performed under the XI rib of 5-6 cm in children, 8 - 10 cm in adults. We briefly describe the technique of the proposed by us technique of subadventitial resection of the ureter followed by pyeloureteroplasty.

After dissection of the pelvioureteric segment with periureteral tissue over the UPJ, the ureteral artery, which is located in medial side, is visualized (Figure 1), which is a continuation of the pelvic artery branched from the renal artery; parallel to it, an incision is made with a scalpel No. 15 on the adventitial layer on both sides approximately 2 mm from the artery longitudinally parallel to the ureteral artery in the avascular zone. Dissection of the adventitial layer of the ureter is completed using curved mosquito forceps. When the adventitial layer is dissected after two parallel incisions to the artery, approximately half of this layer remains above the ureter, and the other half remains together with the ureteral artery (Figure 2).

Dissection of the adventitial layer is performed approximately 3 cm above the ureter and 1 cm above the pelvis: In the presence of an accessory artery to the lower pole of kidney and the need for an antevasal anastomosis, the dissection length is increased by 1 cm to prevent compression of the ureteral artery from the accessory renal artery. After dissection of the adventitial layer of the ureter, together with the artery, a subadventitial resection of the ureter and pelvis is performed. An incision in the ureter of about 1.2-1.4 cm is made on the medial side of the ureter where the adventitia layer was dissected. After placing the double J ureteral stent, a continuous 6/0 suture is applied with absorbable monofilament suture (Figure 3).

During exploration in 58 cases fibromuscular stenosis UPJ was detected, in 47 cases reason of hydronephrosis was crossing accessory vessels, in 3 cases ureteral valves was revealed. When there are accessory vessels to the lower pole of the kidney, an antevasal anastomosis is performed, while the dissected adventitious layer of the ureter remains behind the accessory artery.

In one 17-year-old patient, left-sided UPJ stenosis with an accompanying horseshoe kidney was detected and an isthmotomy, pyeloureteroplasty, and wedge-shaped resection of the lower pole of the kidney were performed (resection of the kidney parenchyma compressing the proximal ureter).

In 12 patients, pyeloureteroplasty was performed without using a double J kidney stent. In the rest cases, antegrade stenting of the ureter was used, which was removed after 9-45 days (usually after 2 weeks) of the postoperative period.

Multiple data point's analysis performed, including patient age, grade of hydronephrosis, and presence of crossing vessels, operative time, and length of hospital stay.

On ultrasonography we studied anteroposterior pelvic diameter and parenchymal thickness (mm) comparatively in preoperative and postoperative period after 3 month of surgery. Complete success was defined as the absence of any clinical symptoms (a pain scale 0 – for signs of no pain), combined with a significant reduction of hydronephrosis (reduction by at least 1 Society for Fetal Urology (SFU) grade based on ultrasonography or IVU, in suspected cases no sign of obstruction on IVU (Figure 4) and/or diuretic renography.

Results

The average mean operative time for ureteropyeloplasty was 102 minutes (78 – 130). The mean hospital stay was 3.7 days (2 – 14 days).

Postoperative complications were observed in five patients. On the basis of Clavien-Dindo classification, 1 case (bacteruria) corresponds to I degree, 2 cases (urine leak and urosepsis) to II degree, 2 cases (restenosis and incorrect location of double J stent) to III degree. Repeated surgical interventions were performed in two patients.

In the first case, in a 28-year old men patient with diabetes mellitus II, subadventitial pyeloureteroplasty was performed without a double J stent. Urine leak was observed in the postoperative period, which was an indication for stenting of the ureter. After stent removal, hydronephrosis was persisted and after 3 months, open reureteropyeloplasty was performed.

In second patient – 7 years old girl in postoperative period also were observed urine leak by drain tube and revealed that the ureteral stent is incorrectly located. The attempt of endoscopic removal of the stent was not successful due to the small diameter of the ureter and therefore the stent was removed by open surgery and a double J stent was installed endoscopically. Postoperative course was smooth and grade of hydronephrosis was diminished (from III to II).

Urosepsis and urinoma were observed in patients for whom ureteral stents were not established during surgery. Ureteral stent placement and conservative therapy have proven effective in both cases. Urinary tract infection requiring long-term antibiotic therapy was observed in a patient with a single kidney in whom stenting lasted for a relatively long time - 45 days. After this observation, ureteral stents were usually removed early - after 2 weeks, while antibiotic therapy continues.

It should be noted that the 5 complications observed by us were not related to the procedure of plastic surgery and were caused by the absence or incorrect location of the ureteral stent. Satisfactory functional and morphological results were achieved in all patients with complications.

Table 1 Laparoscopic and open pyeloureteroplasty complications (our results in comparison with literature data)

	Laparoscopic - Anderson-Hynes (Tan HJ et al. 2011) [6]	Retroperitoneo- scopic–Ander- son-Hynes (Blanc et al. 2013) [7]	Laparoscopic (14); Open (69) - Anderson-Hynes (Salih EM. 2015) [8]	Open subadventitial Anderson-Hynes (our results)
Patients/any complications	102/32 (31%)	104/13 (12.5%)	83/10 (12%)	108/5 (4.6%)
Restenosis	18	2	5	1(reoperation)
Reoperation	16: endopyelo-tomy – 10; nephrectomy - 6	2	5: replasty-1, endopyelotomy-4	2: replasty-1, ureteral stend extraction – 1
Conversion	2	3	-	-
Parenchimal injury	-	2	-	0
Stent complication	5	Reposition double J stent – 2	Reposition double J stent - 1	1(reoperation)
urine leak	18	3	1	1
Urinar tract infection	-	-	-	2(bacteriuria-1, urosepsis–1)

Post-operative follow-up revealed improved renal function and the disappearance of hydronephrosis (especially in children) or a decrease in hydronephrosis by at least in 1 grade (in adult patients) in all cases (Table 1).

Discussion

Open dismembered pyeloureteroplasty by Anderson-Hynes considered the gold standard of care for the treatment of UPJ stenosis with relatively high success rate [1,7]. In the last quarter century, laparoscopic or retroperitoneoscopic dismembered pyeloureteroplasty has been successfully introduced into clinical practice. The advantages of laparoscopic pyeloureteroplasty over open surgery are the possibility magnified vision, low morbidity regarding the postoperative analgesia and shorter hospital stay, minimal incision site scar. However, it is still a more lengthy procedure with higher re-treatment rate (7 - 18%) as compared to OP [3,9].

Our experience shows that a pyeloplasty with subadventitial resection of the ureter and the use of atraumatic surgical techniques, miniaturization of the incision, the use of subcutaneous sutures can improve the postoperative period: reduce hospital days (on average 3.7 days), the need for analgesics and provide a cosmetic effect.

Despite the advancing of surgical technique with open, also with laparoscopic pyeloureteroplasty, a relapse of the disease is observed in 7-9% of cases, which is a consequence of restenosis in the anastomosis [3]. The main reason for the development of stenosis in the area of anastomosis, in our opinion, is insufficient blood circulation and the development of ischemia of the proximal ureter with dismembered pyeloureteroplasty; because, at totally dismembered ureteroplasty resection of the ureter is accompanied by interruption of the integrity of the ureteral artery [5].

The method we have proposed - subadventititial dismembered pyeloureteroplasty allows us removing of the fibromuscular-dysplastic-stenotic changed UPJ preserve of the integrity of ureteric artery located in subadventious layer and protect ureteric blood circulation. An analysis of the results of subadventitial pyeloureteroplasty in 106 patients proves the effectiveness of the proposed technique in the prevention of restenosis in the area of anastomosis.

In our practice, restenosis was observed only in one case, which was, in our opinion, a consequence of inadequate drainage of the kidney, when pyeloureteroplasty without stenting of the ureter was chosen. The second reoperation was carried out by us regarding the incorrect location of the double J stent. The other 2 serious complications (urinoma and sepsis) occurred in a group of patients without the use of ureteral stents. In this aspect, our data are corresponds to the literature, which indicate the same complications in the group of patients without ureteral stenting [9].

Among the of kidney abnormalities concomitant with the UPJ stenosis, the horseshoe kidney attracts attention. With this pathology, pyeloureteroplasty is usually accompanied by isthmotomy and lateralization of the kidney [10]. In our observation, a different surgical tactic was chosen. A short accessory artery approached the lower pole of the left part of the horseshoe kidney, which rendered the lateralization of the kidney impossible. After subadventitial dismembered pyeloureteroplasty and isthmotomy, we observed that the lower pole of the kidney continues to compress the proximal part of the ureter. To eliminate this compression, we were forced to perform a partial wedge-shaped resection of the lower pole of the kidney. Examination after 6 months showed the disappearance of hydronephrosis completely.

Conclusion

In conclusion, our experience in the treatment of patients with hydronephrosis, who underwent an open dismembered pyeloureteroplasty according to Anderson-Hynes using offered by us new method - subadventitial resection of the ureter, shows that maintaining the integrity of the ureteric artery and improving blood circulation in the anastomosis area can reduce complications during surgical treatment of this group patients, in particular, to provide prevention of restenosis.

References

1. Klingler HC, Remzi M, Janetschek G, Kratzik C, Marberger MJ. Comparison of open versus laporoscopic pyeloplasty techniques in treatment of uretero-pelvic junction obstruction. *European Urology* 44. 2003; 340-345. doi: 10.1016/s0302-2838(03)00297-5.
2. O'Reilly PH, Brooman PJ, Mak S, Jones M, Pickup C, Atkinson C, et al. The long-term results of Anderson-Hynes pyeloplasty. *BJU Int.* 2001; 87:287–9. doi: 10.1046/j.1464-410x.2001.00108.x.
3. Jacobs BL, Lai JC, Seelam R2, Hanley JM, Wolf JS Jr, Hollenbeck BK, Hollingsworth JM, Dick AW, Setodji CM, Saigal CS. The Comparative Effectiveness of Treatments for Ureteropelvic Junction Obstruction. *Urology*. 2018; 111:72-77. DOI: 10.1016/j.urology.2017.09.002
4. Anderson JK, Kabalin JN, Cadeddu JA. Surgical anatomy of the retroperitoneum, adrenals, kidneys, and ureters. İn Campbell's *Urology*. 2008; 33-96.
5. Kogan BA. Disorders of the ureter and ureteropelvic junction. In Smith´s General Urology, Edited by Tanagho FA, McAninch JW. XVII edition. 2012; 559-573 DOI:10/1036/0071457372
6. Tan HJ, Ye Z, Roberts WW, Wolf JS. Failure after laparoscopic pyeloplasty: prevention and management. *J Endourol.* 2011; 25(9):1457-62. doi.org/10.1089/end.2010.0647.
7. Blanc T, Muller C, Abdoul H, Peev S, Paye-Jaouen, Peycelon M. et al. Retroperitoneal laparoscopic pyeloplasty in chilfren: long-term outcome and critical analysis of 10-year experience in a teaching center. *European Urology* 63. 2013; 565-572. doi: 10.1016/j.eururo.2012.07.051
8. Salih EM. Morphological and functional outcome of dismembered pyeloplasty in children with unilateral ureteropelvic junction obstruction. African Journal of Urology. 2015; 21(3):174-180 https://doi.org/10.1016/j.afju.2015.04.003
9. Maheshwari R, Ansari M S, Mandhani A, Srivastava A, Kapoor R. Laparoscopic pyeloplasty in pediatric patients: *The SGPGI experience. Indian J Urol.* 2010; 26:36-40. doi: 10.4103/0970-1591.60441.
10. Panda SS, Bajpai M, Jana M, Baidya DK, Kumar R. Anderson-Hynes pyeloplasty with isthmotomy and lateropexy in horseshoe kidneys with pelviureteric junction obstruction in children. I*ndian J Urol*. 2014; 30(2):161-3. doi: 10.4103/0970-1591.126897