JOURNAL OF CLINICAL MEDICINE OF KAZAKHSTAN (E-ISSN 2313-1519)
Case Report DOI: https://doi.org/10.23950/jcmk/13360

A clinical case of pityriasis rubra pilaris - juvenile type

Bahrambek Mukhamedov[1], Evelina Koldarova[2], Obid Kurbanov[1]

[1]*Department of Therapeutic Subjects, Tashkent State Dental Institute, Tashkent, Uzbekistan*
[2]*Dermatology Department, Asmo clinic, Tashkent, Uzbekistan*

Received: 2023-04-06.
Accepted: 2023-05-23

J Clin Med Kaz 2023; 20(3):115-118

Corresponding author:
Evelina Koldarova.
E-mail: koldarova7@gmail.com;
ORCID: 0000-0001-9450-4004.

Abstract

Pityriasis rubra pilaris is a rare chronic inflammatory papulo-squamous skin disease, the pathogenesis of which is still unclear. The pathological essence of the disease is associated with a violation of keratinization against the background of hyperactivity of keratinocytes with subsequent inflammation, as well as with vitamin A dysmetabolism and a weakening of the protein-binding fiction of the liver. Unfortunately, treatment is complex with inconsistent improvement from topical therapies, including emollients, keratolytics, corticosteroids, vitamin D analogs, and retinoids. We present a clinical case of the juvenile type of Devergie's disease in a 3-year-old child, which was caused by poisoning.

Key words: pityriasis rubra pilaris, Devergie's disease, juvenile form, systemic retinoids

Introduction

Pityriasis rubra pilaris (PRP) - heterogeneous, chronic, inflammatory papulo-squamous skin disease, which is divided into congenital form has an autosomal dominant type of inheritance, and the acquired (sporadic) form is not genetically determined. Most cases are sporadic, but familial forms of the disease have been described, in particular, those associated with mutations in the gene map [1-3]. Although it is generally accepted that the name and description belong to Alphonse Devergie, the first case was reported in 1828 by Claudius Tarral. He noted isolated scaly rashes pierced in the center by hair, on palpation of which a very dense roughness is felt on the surface of the skin [4-9].

Devergie's disease (DD) is a rare disease accounting for 0.03-1.3% of all skin diseases. Its onset occurs in the first or fifth decade of life. The etiology and pathogenesis of dermatosis is still not fully understood, the opinions of modern authors differ. It is thought to be caused by an abnormal immune response to various antigenic stimuli such as infections, trauma, autonomic and hormonal dysfunctions, hepatosis, vaccination, and malignancy [10,11]. In DD, the epidermis is in a hyperkinetic state with an increase in the turnover of follicular keratinocytes. A pathogenic role has been suggested for vitamin A deficiency or dysfunction [12] or a decrease in serum retinol-binding protein, which is the vitamin A transporter [13], along with some clinical similarities to rhinoderma (a skin manifestation of vitamin A deficiency [14].

In 1980, W. Griffiths described five different types of DD based on clinical characteristics, age of onset, and prognosis [15]. Subsequently, Miralles suggested adding a 6th type associated with HIV infection to this classification [9] (Table 1).

Currently, the classification of DD includes three clinical forms:

1. Classical type.
2. Localized juvenile type.
3. Type associated with HIV infection.

DD is characterized by pronounced clinical polymorphism. The most common clinical features are follicular papules progressing to yellow-orange erythroderma with rounded small patches of normal skin and well-circumscribed palmoplantar keratoderma. Lesions are symmetrical and diffuse and appear first on the extensor surfaces of the limbs, shoulders, and buttocks, usually spreading caudally with possible development of erythroderma. The presence of islands of healthy skin is of great clinical importance for the diagnosis of DD, sometimes being one of the most important differential signs [16]. This symptom is the presence of small patches of healthy-looking skin, coin-shaped, about 1 cm in diameter, scattered on an erythrodermic background in any part of the skin. Peeling has a heterogeneous character: the scales on the upper half of the body are small, on the lower - more often large-lamellar. Localization of follicular hyperkeratosis on the back surface of the I-II phalanges of the fingers in the literature is called "Besnier's symptom". The nail plates are often affected, have a yellowish color,

Table 1 Types of Devergie's disease by W. Griffiths (1980) augmented by Miralles

Type	Frequency of occurrence (≈%)	Prevalence of rashes	Clinical characteristics	Course and prognosis
I — classical adult	55	Generalized	Follicular papules, erythroderma with "islands of apparently healthy skin", palmoplantar hyperkeratosis, nail changes. Spreads the faucet audibly	In most cases resolved within 3 years
II — atypical adult	5	Generalized	Ichthyosiform changes on the lower extremities, eczema-like rashes and the appearance of diffuse non-scarring alopecia	Chronic
III — classical juvenile	10	Generalized	Similar to type I, develops in children in the 1st-2nd year of life or in adolescence	In most cases resolved within 3 years
IV — circumscribed juvenile	25	Localized	Well-circumscribed plaques with hyperemia, areas of follicular keratosis with clear boundaries, localized on the skin of the elbows and knees	Resolved in late adolescence
V — atypical or nevoid juvenile	5	Generalized	Follicular hyperkeratosis associated with sclera-like changes in the hands and feet develops in early childhood	Chronic
VI — HIV-associated	<5	Generalized	Typical follicular papules with nodular cystic and pustular acneiform features associated with HIV infection. There is a regression of elements during antiviral treatment	Chronic. Unfavorable prognosis

are striated with longitudinal or transverse furrows, subungual hyperkeratosis is often pronounced. In some cases, there is a deformation of the nail plates of the feet and hands, up to onychogryphosis. Clinical diagnosis of the disease is based on characteristic features: osteofollicular papules, forming the symptom of a "grater"; perifollicular erythema, with a tendency to merge; the presence of "islands of healthy skin" against the background of erythroderma; brick red color of the skin; palmar-plantar hyperkeratosis; nail changes; Besnier's symptom.

The classical juvenile type occurs in the 1st or 2nd year of life. Clinically, it manifests itself in the same way as the classic adult type, only the age of patients differs [17,18]. It differs from the adult type in a more frequent (2 times) onset on the lower half of the body and slow spread. Follicular hyperkeratosis may also occur on the phalanges of the fingers. Compared with the classical adult type, the clinical picture is less pronounced.

Treatment of DD is not an easy task, especially in children. Complex therapy is applied. Currently, drugs that affect the processes of keratinization are retinoids. Today, it has been proven that vitamin A is involved in the regulation and proliferation of many cell types from the moment of embryonic laying and throughout life. The most effective among all synthetic retinoids in the treatment of DD is Neotigazon at a dose of 0.5–0.7 mg/kg/day [7–9, 19]. The drugs of first choice are systemic retinoids and methotrixate. According to various authors, alternative methods of treatment may be Prednisolone (15-20 mg / day), Diprospan (2.0 / m once every 10 days № 3) and cytostatics: prospidin (50-100 mg / m daily for a course of 2.0–3.0 g) or methotrexate (15 mg IM once every 7 days) [9, 20]. External treatment while taking retinoids is of no fundamental importance, however, it significantly improves the general condition of the patient and improves the quality of his life. Both classic ointments and creams and modern dry skin care products are used. To eliminate massive horny layers, ointments with 2–5% salicylic acid, 10% urea, 1–20% malic acid are prescribed. In addition, physiotherapy is used to treat patients with DD. Useful are warm general baths with sea salt, starch baths, followed by the use of keratolytic ointments, phonophoresis of hydrocortisone cream with the addition of aevit. The prognosis for life is favorable, with regard to cure - uncertain [21]. The question of the advisability of using ultraviolet irradiation in such patients has not yet been resolved; the opinions of modern authors are contradictory and require further study [22].

Case presentation

We present a case of the classic juvenile type of Devergie's disease. A married couple with a 3-year-old child came to the Asmo clinic with complaints of skin rashes and itching. The rash was observed in all family members, appeared at about the same time, they associated with poisoning after eating the local dish "shish kebab", although the exact cause was not established. The father of the family had urticarial rashes, acute urticaria was diagnosed, the mother had rashes on the skin of the trunk and extremities in the form of pink spots, 1 cm in diameter, no peeling was observed. She was diagnosed with allergic dermatitis. At the time of treatment, the child had a pronounced dryness of the entire skin, slight hyperemia in the area of the cheeks, upper and lower extremities, and finely lamellar peeling in the area of the folds (Figures 1-3). No concomitant somatic diseases were found in the child. During luminescent diagnostics, no pathological glow was detected in the rays of the Wood's lamp. A diagnosis of Atopic Dermatitis was made.

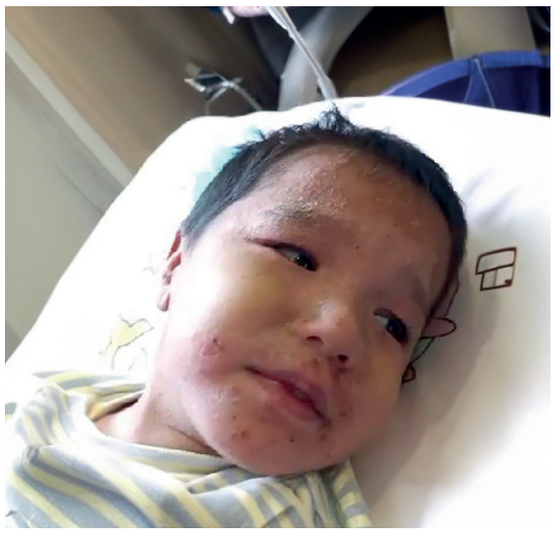

Figure 1 - Severe dryness, finely lamellar peeling, slight hyperemia in the cheeks, pinpoint excoriations covered with hemorrhagic crusts.

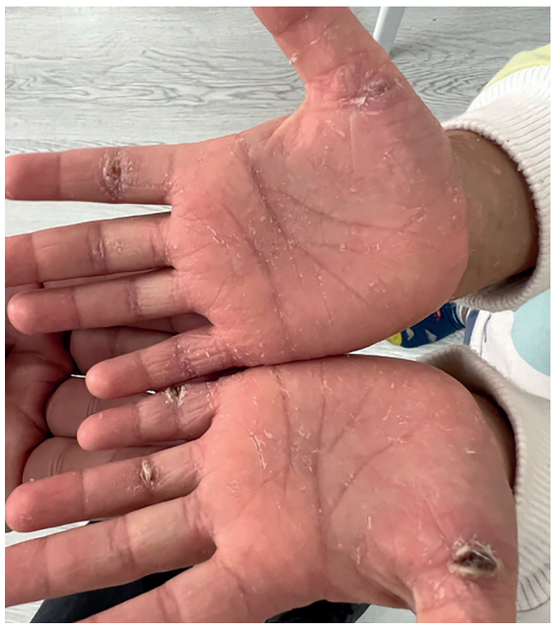

Figure 2 - Salmon color of the skin of the palms, dryness, the presence of deep cracks.

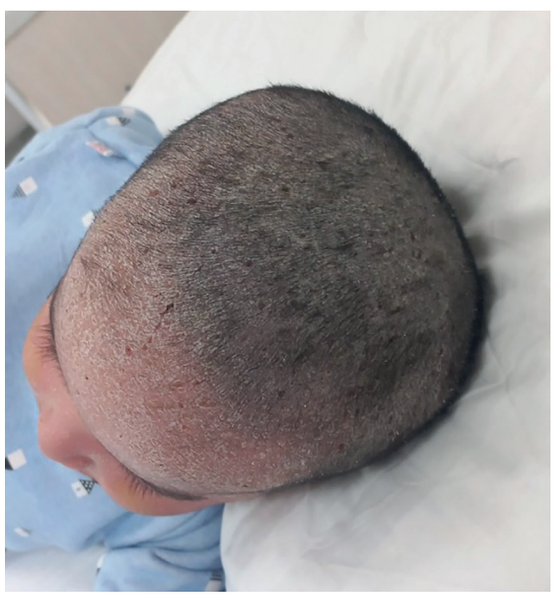

Figure 3 - Finely lamellar peeling on the skin of the scalp.

All three were prescribed desensitizing therapy, enterosorbents, antihistamines, local glucocorticosteroid ointments, and a moisturizing emollient cream. After 10 days, there was a positive dynamic in the treatment - the rashes in the father and mother were resolved, however, in the child, the rashes acquired a generalized character. At the follow-up consultation:

Status localis: Skin - pathological process is subacute, widespread, symmetrical, inflammatory. It is represented by erythematous-squamous elements, multiple follicular small papules without a tendency to merge on the skin of the scalp with a predominant lesion of the skin of the trunk and upper extremities (Figures 1-3). After receiving therapy for "atopic dermatitis", islands of healthy skin appeared. The patient was hospitalized for inpatient treatment at «Asmo clinic». A diagnostic biopsy was recommended to confirm the clinical diagnosis of Devergy's disease.

According to the test results: In the general blood test - leukocytes 11.4 x 10 9/l (↑); neutrophils - 7.1 x 109 (↑); eosinophils - 6%; hemoglobin 109 g/l (↓); ESR - 20 mm/h (↑); IgE - 127.1 IU / ml (N - 0-200.0 IU / ml); In the biochemical analysis of blood - without pathology; 25 OH vitamin D - 78.2 mg / ml - (N - 30-100 adequate level)

The result of the pathomorphological study - There is a pronounced hyperkeratosis with horny invaginations, horny plugs, parakeratosis, pronounced acanthosis with elongation and thickening of the epidermal process, the granular layer of the epidermis is preserved. Perivascular lymphohistiocytic infiltration in the dermis. Skin appendages are preserved. This morphological picture is characteristic of pityriasis rubra pilaris (Devergie's disease) (Figure 4).

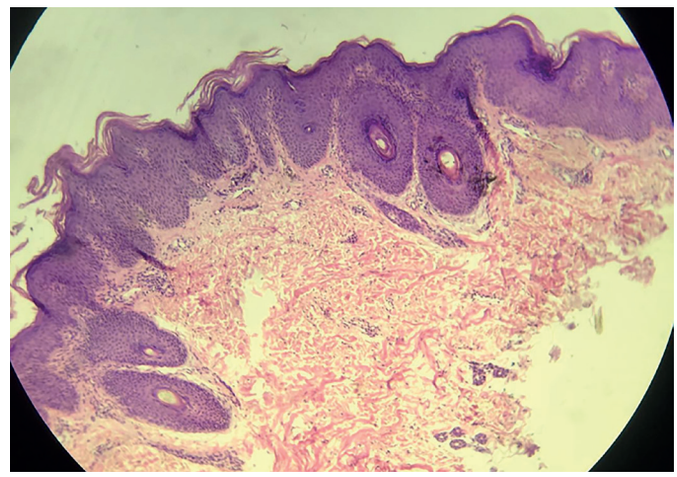

Figure 4 - Histological picture of a biopsy specimen from the skin of the body, stained with Hematoxylin-eosin. Zoom x 100.

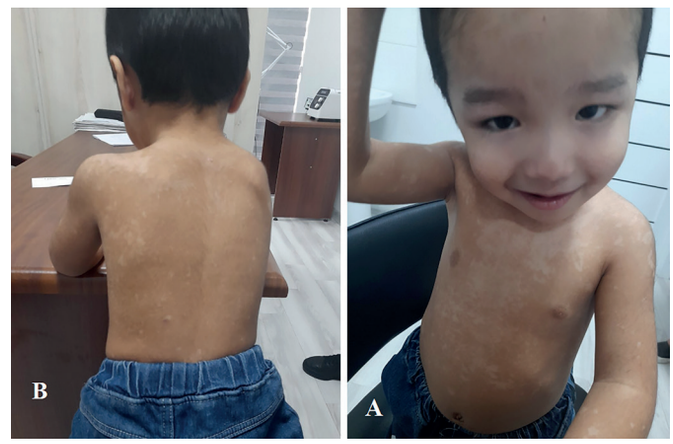

Figure 5A and 5B - Condition after treatment.

The patient received the following treatment: sodium chloride solution 0.9% -100.0 + calcium gluconate solution 10% -2.0 i/v № 7; solution of dexamethasone 4 mg -1.0 i/m № 3; Cap. Retinol acetate 33,000 IU, 1 capsule x 2 times a day; Caps. Bifloran Neo 1 capsule x 2 times a day No. 10; Syrup Zodak 2.5 mg x 1 time per day № 10; Dexeryl cream; Cream Mesoderm (Mometasone furoate) - 1 time per day; Physiotherapy - PUVA therapy № 10.

During the treatment, a positive clinical effect was noted in the form of resolution of the majority of rashes, which confirms the correct choice of therapy (Figures 5A and 5B).

Conclusion

This clinical case is of particular interest, since Devergie's disease is a rather rare dermatological disease in pediatric practice. When working with children, a dermatologist should conduct a thorough differential clinical diagnosis with such diseases as seborrheic dermatitis, psoriasis, atopic dermatitis, follicular ichthyosis, lichen planus, lichenoid parapsoriasis, etc., so as not to miss the disease. The number of diseases for differential diagnosis proves the diversity of Devergie's disease.

Disclosures: There is no conflict of interest for all authors.

Funding: None

Acknowledgements: None

References

1. Howe K, Foresman P, Griffin T, Johnson W. Pityriasis rubra pilaris with acantholysis. *J Cutan Pathol*. 1996; 23(3):270–274. https://doi.org/10.1111/j.1600-0560.1996.tb01478.x
2. Fuchs-Telem, D., Sarig, O., van Steensel, M. A. M., Isakov, O., Israeli, S., Nousbeck, J., Richard, K., Winnepenninckx, V., Vernooij, M., Shomron, N., Uitto, J., Fleckman, P., Richard, G., & Sprecher, E. Familial Pityriasis Rubra Pilaris Is Caused by Mutations in CARD14. *The American Journal of Human Genetics.* 2012; 91(1):163–170. https://doi.org/10.1016/j.ajhg.2012.05.010
3. Takeichi T, Sugiura K, Nomura T, Sakamoto T, Ogawa Y, Oiso N, Futei Y, Fujisaki A, Koizumi A, Aoyama Y, Nakajima K, Hatano Y, Hayashi K, Ishida-Yamamoto A, Fujiwara S, Sano S, Iwatsuki K, Kawada A, Suga Y, Shimizu H, McGrath JA, Akiyama M. Pityriasis Rubra Pilaris Type V as an Autoinflammatory Disease by CARD14 Mutations. *JAMA Dermatol.* 2017; 153(1):66-70. https://doi.org/10.1001/jamadermatol.2016.3601
4. Berenbein B. A., Studnitsin A. A. et al. Differential diagnosis of skin diseases [in Russian]. Moscow: *Medicine*, 1989. 672 p.
5. Elkin V. D., Mitryukovsky L. S. Selected dermatology. Rare dermatoses and dermatological syndromes. Handbook for the diagnosis and treatment of dermatoses [in Russian]. *Perm*, 2000. 699 p.
6. Mordovtsev V.N. Hereditary diseases and malformations of the skin [in Russian]. M.: *Nauka*, 2004. 174 p.
7. Kalamkaryan A. A., Kubanova A. A., Akimov V. G., Arifov S. S. Pityriasis rubra pilaris Devergie [in Russian]. *Bulletin of dermatology and venereology*. 1990; 6:20–23.
8. Kubanova A. A., Akimov V. G. Differential diagnosis and treatment of skin diseases: Atlass reference book [in Russian]. M.: *OOO Medical Information Agency,* 2009. 304 p.
9. European Guidelines for the Treatment of Dermatological Diseases / Ed. A. D. Katsambasa, T. M. Lotti. M. [in Russian]. *MEDpress-inform,* 2008. 736 p
10. Yang CC, Shih IH, Lin WL, Yu YS, Chiu HC, Huang PH, Cheng YW, Lee JY, Chen W. Juvenile pityriasis rubra pilaris: report of 28 cases in Taiwan. *J Am Acad Dermatol.* 2008; 59(6):943-8. https://doi.org/10.1016/j.jaad.2008.07.054
11. Möhrenschlager M, Abeck D. Further clinical evidence for involvement of bacterial superantigens in juvenile pityriasis rubra pilaris (PRP): report of two new cases. *Pediatr Dermatol.* 2002;19(6):569. https://doi.org/10.1046/j.1525-1470.2002.00236_5.x
12. White KL. Pityriasis rubra pilaris. Dermatol Online J. 2003; 9(4):6.
13. Evangelou G, Murdoch SR, Palamaras I, Rhodes LE. Photoaggravated pityriasis rubra pilaris. *Photodermatol Photoimmunol Photomed*. 2005; 21(5):272-4. https://doi.org/10.1111/j.1600-0781.2005. 00179.x
14. Di Stefani A, Orlandi A, Chimenti S, Bianchi L. Phrynoderma: a cutaneous sign of an inadequate diet. *CMAJ*. 2007; 177(8):855-6. https://doi.org/10.1503/cmaj.070086
15. Griffiths WA. Pityriasis rubra pilaris: the problem of its classification. J. Am. Acad. *Dermat*. 1992; 1:140-142. https://doi.org/10.1016/s0190-9622(08)80543-9
16. Muhamedov, B., Kurbanov, O. J., & Koldarova, E. V. Erythrodermic form of pityriasis rubra pilaris Devergie (clinical case) [in Russian]. Journal "Medicine and Innovations".2022; 2:383-392.
17. Ivanov O.L. Pityriasis rubra pilaris Devergie [in Russian]. *Skin and venereal diseases. M*., 2007. p.154-155.
18. Olisova O.Yu. et al. The erythrodermic form of Devergie's disease [in Russian]. *Rus. J. cutis and veneral diseases.* 2014; 1:18-20.
19. Rational pharmacotherapy of skin diseases and sexually transmitted infections: Handbook. for practicing physicians, ed. Kubanova A. A., Kisina V. I. M. [in Russian]. *Litera*, 2005. 882 p.
20. Holliday A. C., Megan N. M., Berlingeri-Ramos A. Methotrexate: Role of Treatment in Skin Disease. *Skin Therapy Letter.* 2013; 18(3).
21. Romanenko I.M. et al. Pityriasis rubra pilaris Devergie [in Russian]. *Treatment of skin and venereal diseases. M.*; 2006; 429-431.
22. Osorio F., Magina S. Phototherapy and Photopheresis. *Expert Rev Dermatol*. 2011; 6(6):613–623. https://doi.org/10.1586/edm.11.71