JOURNAL OF CLINICAL MEDICINE OF KAZAKHSTAN (E-ISSN 2313-1519)
Case Report DOI: https://doi.org/10.23950/jcmk/14008

A rare neurological complication of COVID-19: Pediatric Miller Fisher Syndrome. A case report

Yerdan Mukhaliyev, Rahmatulla Ulmira, Mayufi Amina, Zhylkybay Zhansaya

Department of Pediatric Infectious Diseases, Asfendiyarov Kazakh National Medical University, Almaty, Kazakhstan

Received: 2023-10-25.
Accepted: 2023-12-04

J Clin Med Kaz 2023; 20(6):73-77

Corresponding author:
Yerdan Mukhaliyev.
E-mail: erdandoctor@gmail.com;
ORCID: 0000-0002-0996-1428

Abstract

The SARS-CoV-2 pandemic has significantly transformed the world. While it was initially viewed as a respiratory virus, it has now been found to cause cardiovascular, gastrointestinal, and psychological complications. Moreover, the nervous system (NS) is also greatly affected. Research has identified dizziness, headaches, as well as disturbances in one's taste and smell abilities as the most frequent symptoms of NS involvement. Even more significant changes may occur in patients who get infected with SARS CoV-2, such as the development of acute cerebrovascular disorders (stroke), multiple sclerosis, acute disseminated encephalitis, Guillain-Barré syndrome, encephalitis, and myelitis. It is important to note these potential complications and monitor patients closely. A retrospective study conducted in Wuhan, China revealed that CNS (central nervous system) involvement occurred three times more frequently than PNS (peripheral nervous system) involvement. This emphasizes the critical importance of studying and describing CNS manifestations. This case report depicts Miller Fisher syndrome in a 5-month-old infant after SARS CoV-2 infection and explores literature on pediatric cases and potential pathogenic mechanisms.

Keywords: SARS-CoV-2, Miller Fisher Syndrome, COVID-19, neurological complications, immune-mediated neuropathy, anti-GQ1b

Introduction

Miller-Fisher Syndrome (MFS) is an acute peripheral neuropathy that is considered a clinical variant of Guillain-Barré syndrome. It arises from the impact of various viral, bacterial, and fungal pathogens. An infectious agent triggers an autoimmune inflammatory response, which results in damage to the peripheral nerves, followed by demyelination and subsequent axonal injury. This syndrome presents a clinical triad consisting of ophthalmoplegia, ataxia, and areflexia, with the potential addition of moderately pronounced peripheral tetraparesis. MFS combines both central nervous system involvement, which affects the cerebellar structures leading to ataxia, and peripheral nervous system involvement, particularly the third, fourth, or sixth cranial nerves, as well as peripheral nerves, resulting in ophthalmoplegia and ataxia [1]. The incidence of MFS generally accounts for a small subset of GBS patients, making up only 5%. However, a study conducted in Asia revealed a higher incidence of GBS in Asian countries [2]. With the increasing incidence of neurological complications associated with SARS CoV-2, there is concern that it could potentially contribute to existing MFS incidence numbers in the future. Typical laboratory findings of Guillain-Barre syndrome (GBS) reveal albumin-cytologic dissociation, which suggests a rise in protein level within the cerebrospinal fluid (CSF), while the cell count remains in the normal range [3]. Additional diagnostic methods that bolster suspicion of GBS include electromyography (EMG) and magnetic resonance imaging (MRI), along with the identification of anti-GQ1b antibodies. However, despite the fact that anti-GQ1b antibodies are positive in the majority of GBS patients (up to 90%), their absence does not exclude the diagnosis [4,5]. We herein report a retrospective case of Miller Fisher syndrome development in a 5-month-old infant subsequent to SARS CoV-2 infection. Possible pathogenic mechanisms related to this case are also discussed.

Case presentation

A 5-month-old infant was admitted to the Pediatric Clinical Infectious Disease Hospital in Almaty with a history of high fever of up to 38.5°C, coughing, sore throat, nasal discharge, and fatigue. The onset of the disease was sudden and manifested as refusal to breastfeed and irritability. On the third day of illness, the child displayed a temperature of up to 38.5°C. The mother initially believed that the symptoms indicated the

emergence of new teeth and she administered her own gingival pain reliever and ibuprofen. On the fourth day of symptoms, the mother scheduled an appointment with a pediatrician at a private medical center. Following examination, the child was diagnosed with acute respiratory viral infection (ARVI), acute pharyngitis, and acute otitis media. The child was then sent for home treatment. However, the next morning the infant's condition rapidly worsened by developing shortness of breath and the emergence of neurological symptoms, including left ptosis, general fatigue, and loss of movement in the extremities, and lethargy. This led to the family calling for an ambulance and seeking care at the Pediatric Infectious Disease Hospital.

Based on the medical history, the child demonstrated age-appropriate developmental milestones. The child only received prophylactic vaccinations at birth, and all other vaccinations were declined due to written parental refusal. There was no family history of autoimmune or neurological disease. The epidemiological history indicates a recent occurrence of acute respiratory viral infection (ARVI), which occurred approximately two weeks ago with mild symptoms that improved within three days. Due to receiving treatment at home, the infant was not seen by a specialist and was not tested for possible causes of ARVI.

Upon admission and objective examination, the infant presented with severe and unstable condition due to type 2 respiratory failure, metabolic acidosis, and neurological impairment. The child appeared lethargic, intermittently restless, and moaning. Pupil examination revealed bilaterally dilated pupils with weak light response. Weak muscle tone and reflexes were found in both upper and lower extremities. No signs of meningeal irritation were noted. The fontanelle measured 2.5x2.5cm with no bulging. The oropharyngeal exam revealed only erythema of the posterior pharyngeal wall and tonsils. Lung auscultation revealed diminished respiratory sounds with crackles in the lower lobes, indicating moderate mixed-type dyspnea at rest with a respiratory rate of 54 bpm. Muffled heart sounds and tachycardia (185 bpm) were noted. Abdominal palpation showed moderate hepatomegaly and splenomegaly but was painless. The patient remained hemodynamically stable. Due to the severity of the infant's condition, he was promptly referred to the pediatric intensive care unit.

A lumbar puncture was conducted upon admission, revealing elevated protein levels and a normal cell count in the cerebrospinal fluid (CSF). The cell count was 3 cells/microliter with 100% lymphocytes and protein levels were 920 g/l. The CSF appeared clear with normal pressure and glucose levels, indicating albumin-cytologic dissociation. Subsequently, an ELISA analysis of the CSF was performed to detect antiGQ1b IgG and IgM antibodies, yielding a negative result (reference range <1700 BTU). After one week, the Gram stain and CSF culture results demonstrated no growth. Furthermore, the respiratory viral PCR panel tests for SARS-CoV-2, flu, and RSV were all negative. A chest X-ray revealed bilateral multifocal pneumonia and first degree thymus enlargement (Figure 1). Notably, the serological panel showed negative results for chlamydia trachomatis, toxoplasma gondii, and herpes simplex, but only CMV IgG antibodies were positive. The general blood count test revealed an increase in leukocytes (22*103/mcL), accompanied by elevated levels of neutrophils (75%) and reduced levels of lymphocytes (14%). The nerve conduction test showed indications of impairments in both sensory and motor nerve conduction, with the absence of both H reflex and F waves.

In the days following admission to the pediatric intensive care unit, the patient's condition deteriorated with the disappearance of the gag reflex, development of swallowing difficulty, and right-side facial muscle paralysis, indicating cranial nerve involvement. A brain CT scan was performed to rule out any other cranial conditions that could be causing these symptoms. The CT scan revealed benign enlargement of the frontoparietal subarachnoid space without signs of hemorrhage or tumor, as shown in Figure 2.

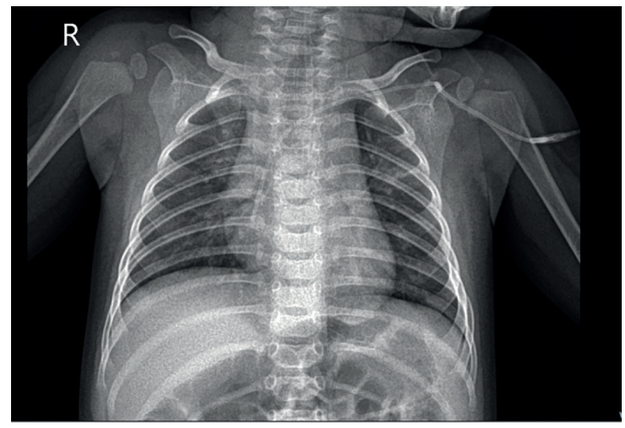

Figure 1 - Chest radiograph showing bilateral multifocal pneumonia with first degree of thymus enlargement.

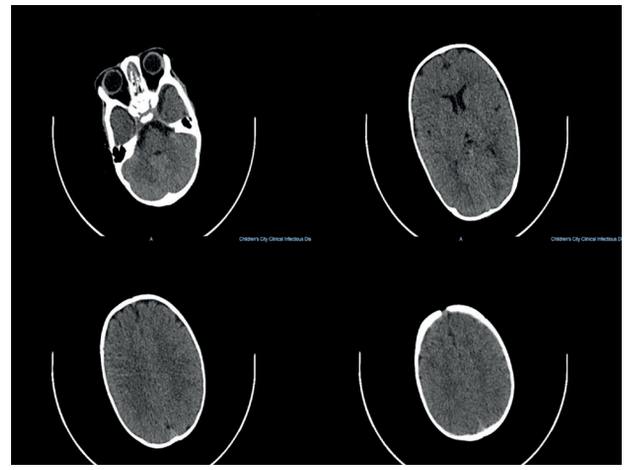

Figure 2 - Cranial CT scan: benign enlargement of frontoparietal subarachnoid space.

Further investigation for possible causes that could have triggered Miller Fisher Syndrome revealed positive IgG to N-protein of SARS-Cov-2 - 4.85s/co while IgM to N-protein of SARS-Cov-2 was negative. Based on patient's symptoms, epidemiological history and laboratory findings a clinical diagnosis of Miller Fisher Syndrome was made. The diagnosis was confirmed by using the Brighton Collaboration GBS Working Group criteria with 1 level of certainty (Figure 3).

	Level of diagnostic certainty			
Symptoms	**1**	**2**	**3**	**4**
Symmetric flaccid limb weakness	+	+	+	+/-
Decreased or absent deep tendon reflexes in weak limbs	+	+	+	+/-
Monophasic course and time between onset of signs 12 hours to 28 days	+	+	+	+/-
Cerebrospinal fluid (CSF) cell count <50/ml	+	+/-	-	+/-
CSF protein level is greater than normal value	+	+/-	-	+/-
Absence of alternative diagnosis for weakness	+	+	+	+/-
Nerve conduction test results is consistent with one of the subtypes of Guillain Barre Syndrome	+	+/-	-	+/-

Figure 3 - Brighton criteria for Guillain Barre Syndrome. (+) present, (-) absent, (+/-) present or absent.

Initially prior to ruling out CNS infection empirically ceftriaxone along with acyclovir was given intravenously. In addition to antibiotics and antiviral medicine methylprednisolone was administered. Following completion of differential diagnosis and obtaining laboratory results ceftriaxone and acyclovir were discontinued, and instead, 2g/kg intravenous immunoglobulin (IVIg) was given. Overall, signs of cranial nerve impairment persisted for 6 days. After being monitored and treated in pediatric intensive care unit for 13 days gag reflex, difficulty in swallowing and facial paralysis resolved. Subsequently, the patient was further referred to the pediatric neurology department. Following a total hospital stay of 20 days, the patient was discharged with mild muscle weakness in extremities.

Discussion

Prior to the COVID-19 pandemic, the global incidence of Guillain-Barré Syndrome (GBS) was approximately 1-2 cases per 100,000 people, and the manifestation variant of Miller-Fisher Syndrome (MFS) accounted for only 5% of GBS cases [4,6]. A systematic review conducted on nervous system involvement triggered by SARS CoV-2 shows 25 cases of MFS associated with COVID-19 in adults, and four cases in children [7]. Searching for previously reported relevant scientific articles and literature found no cases of MFS associated with SARS cov-2 in the Republic of Kazakhstan. However, there was only one case of MFS has been described in the Russian Federation [8,9]. Researchers who conducted genetic analyses of COVID-19 recovered patients discovered that Asians and individuals of African descent experienced more severe outcomes. It is essential to note that patients experiencing severe COVID-19 symptoms may suffer from neurological impairment due to rapid clinical deterioration or worsening of their condition [10].

The pathogenesis of CNS involvement in COVID-19 remains variable. In studies describing cases of meningitis and encephalitis, autopsy material exhibited SARS-CoV-2 RNA [11,12]. This finding is explained by the viral particles entering through the endothelial cells of capillaries, similar to how it affects other organs and systems. The mechanism of injury causing MFS-like symptoms is thought to be immune mediated rather than direct viral neurotropism, as SARS-CoV-2 RNA was not detected when examining cerebrospinal fluid (CSF) from affected patients [13,14]. Several studies have shown that the immune-inflammatory response to COVID-19 and the heightened production of IL-1, IL-6, IL-17, IL-22, and TNF-α lead to nervous system involvement that is as significant as that in other organs [15,16].

Furthermore, the hypothesis is supported by the finding that in the majority of cases, the time span between the onset of COVID-19 symptoms and the onset of neurological symptoms exceeded two weeks, suggesting a post-infection autoimmune process [17]. Another crucial point to consider is the prompt and favorable response to treatment observed after the administration of intravenous immunoglobulins. Thus, the immune-mediated neuropathy triggered by COVID-19 could be induced by cross-reactivity and molecular mimicry between SARS-CoV-2 antigenic epitopes and carbohydrate fragments of surface cranial nerve glycoproteins [18]. Given this factor, it is justifiable to examine both the direct neurotropism of SARS-CoV-2 in causing complications like anosmia, encephalitis, and meningitis, as well as the immune-mediated mechanism in the origin of Miller-Fisher Syndrome (MFS) or Guillain-Barré Syndrome (GBS) [19,28]. The diagnosis of MFS cases are based on history of symptoms and physical examination where presentation of classical triad such as ataxia, areflexia, and ophthalmoplegia can be found. Furthermore, indirect changes in cerebrospinal fluid (CSF) or nerve conduction studies corresponding to the polyneuropathy patterns described for MFS when CSF sampling is not accessible is also useful. For CSF analysis, slight pleocytosis, an elevated protein concentration, and the absence of other microorganisms in PCR analysis or bacteria culture test [3,20]. This is also supported by the presence of anti-GQ1b antibodies in some patients, which are commonly associated with Miller Fisher syndrome. Anti-GQ1b antibodies bind to gangliosides on the oculomotor nerve, abducens nerve, vagus nerve, limb muscle spindle, and brainstem network structure by blocking acetylcholine excretion from the motor terminals resulting in symptoms including ataxia, weakness, breathing difficulties, and areflexia [21].

In our patient apart from anti-GQ1b antibodies the classic clinical symptoms and CSF changes were present. The absence of anti-GQ1b antibodies considers the case of MFS to be atypical as the majority of MFS cases (85-90%) are known to have positive anti-GQ1b antibodies particularly in variants with ophthalmoplegia [4,22]. However, despite being positive in majority of the patients with MFS absence of antiGQ1b antibodies does not rule out the diagnosis [23]. Additionally, the systematic review published in 2021 by Martins-Filho et al revealed that significant number of MFS cases were anti-GQ1b antibody negative [24].

We think in our case there were several factors that contributed to patient's condition. Firstly, the history of contracting an acute respiratory infection prior to development of neurological complications which further proved to be SARS-CoV-2 infection by identification of IgG to N-protein of SARS-Cov-2. It is worth noting that according to multicenter study conducted in South Korea among the children to see antibody responses to SARS-CoV-2 revealed that anti-SARS-Cov-2 IgG antibodies become detectable in all children after 14 days from onset of SARS-Cov-2 [25]. Apart from molecular mimicry that is well known in development of cross-reaction against myelin of the host nerves. Another risk factor that could possibly trigger inadequate immune reaction was thymus enlargement identified during chest organ investigation. Given the fact that thymus has a major role in differentiation and maturation of T-cells, thymic enlargement could play an important role in developing many conditions including respiratory distress and autoimmune disorders [26,27]. Finally, the reason for the late hospital admission which led to multifocal pneumonia with type 2 respiratory failure and negative metabolic changes was home treatment and misdiagnosis and underestimation of child's condition. At the time of admission parents could not recall what treatment was prescribed by the private medical center pediatrician and did not present it later.

In conclusion, the case of the 5-month-old infant highlights the challenges in diagnosing and managing neurological complications related to COVID-19. While Miller Fisher Syndrome (MFS) is a rare form of Guillain-Barré Syndrome (GBS), this case emphasizes the importance of increased awareness of unique and less common clinical presentations during the ongoing COVID-19 pandemic.

Several factors contributed to the child's condition. Initially, the respiratory symptoms were misdiagnosed as acute respiratory viral infection (ARVI), leading to a delay in appropriate medical care. Subsequently, the identification of IgG to N-protein of SARS-CoV-2 indicates that the child had previously contracted SARS-CoV-2. This highlights the significance of considering

COVID-19 as a potential trigger for neurological complications, even in young children. The absence of anti-GQ1b antibodies, which are usually related to MFS, in our patient's case highlights the atypical nature of the condition and serves as a reminder that clinical diagnosis should not solely rely on the presence of specific antibodies. The thymus enlargement discovered during chest organ investigation contributes an additional level of complexity to the case. Thymic enlargement can impact immune responses, and its role in contributing to autoimmune disorders and respiratory distress should not be underestimated.

In addition, the rapid and positive response to intravenous immunoglobulin treatment further supports the hypothesis that COVID-19-triggered immune-mediated neuropathy may involve cross-reactivity and molecular mimicry between SARS-CoV-2 antigenic epitopes and cranial nerve glycoproteins. This case adds valuable evidence to the growing body of knowledge regarding the neurological symptoms of COVID-19, emphasizing the significance of timely diagnosis and appropriate treatment. Furthermore, it highlights the necessity for further research to enhance our comprehension of the intricate connection between viral infections, the immune system, and neurological problems. We suggest that healthcare providers should maintain a high level of suspicion for neurological complications, particularly in cases where initial symptoms may be linked to a SARS-CoV-2 infection. This approach can facilitate prompt diagnosis and treatment, which may result in more favorable outcomes among affected individuals.

Disclosures: There is no conflict of interest for all authors.

Acknowledgements: None.

Funding: None.

Patient informed consent: Obtained.

References

1. Lantos JE, Strauss SB, Lin E. COVID-19-Associated Miller Fisher Syndrome: MRI Findings. *AJNR Am J Neuroradiol.* 2020; 41(7):1184-1186. https://doi.org/10.3174/ajnr.A6609
2. Ma YM, Liu TK, Wong V. Guillain-Barre syndrome in southern Chinese children: 32 year experience in Hong Kong. *Pediatr Int*. 2010; 52(1):13-9. https://doi.org/10.1111/j.1442-200X.2009.02951.x
3. Rath J, Zulehner G, Schober B, Grisold A, Krenn M, Cetin H, Zimprich F. Cerebrospinal fluid analysis in Guillain-Barré syndrome: value of albumin quotients. *J Neurol.* 2021; 268(9):3294-3300. https://doi.org/10.1007/s00415-021-10479-9
4. Poyraz T. Miller Fisher Syndrome Associated With COVID-19: A History of Molecular Mimicry and an Up-to-Date Review of the Literature. *Cureus*. 2023; 15(8):e43111. https://doi.org/10.7759/cureus.43111
5. Zhang L, Ma L, Zhou L, Sun L, Han C, Fang Q. Miller-Fisher syndrome with positive anti-GD1b and anti-GM1 antibodies combined with multiple autoimmune antibodies: A case report. *Medicine (Baltimore).* 2023; 102(34):e34969. https://doi.org/10.1097/MD.0000000000034969
6. Gigli GL, Bax F, Marini A, Pellitteri G, Scalise A, Surcinelli A, Valente M. Guillain-Barré syndrome in the COVID-19 era: just an occasional cluster? *J Neurol.* 2021; 268(4):1195-1197. https://doi.org/10.1007/s00415-020-09911-3
7. Favas TT, Dev P, Chaurasia RN, Chakravarty K, Mishra R, Joshi D, Mishra VN, Kumar A, Singh VK, Pandey M, Pathak A. Neurological manifestations of COVID-19: a systematic review and meta-analysis of proportions. *Neurol Sci.* 2020; 41(12):3437-3470. https://doi.org/10.1007/s10072-020-04801-y
8. Neophytou P, Artemiadis A, Hadjigeorgiou GM, Zis P. Miller Fischer syndrome after COVID-19 infection and vaccine: a systematic review. *Acta Neurol Belg*. 2023; 123(5):1693-1701. https://doi.org/10.1007/s13760-023-02336-5
9. Malko V.A., Klimov P.V., Topuzova M.P., Yarush I.V., Simakov K.V., Alekseeva T.M. Miller Fisher syndrome developed after a previous COVID-19 infection (case report). *Neuromuscular Diseases*. 2021; 11(2):56-60. https://doi.org/10.17650/2222-8721-2021-11-2-56-60
10. Raisi-Estabragh Z, McCracken C, Bethell MS, Cooper J, Cooper C, Caulfield MJ, Munroe PB, Harvey NC, Petersen SE. Greater risk of severe COVID-19 in Black, Asian and Minority Ethnic populations is not explained by cardiometabolic, socioeconomic or behavioural factors, or by 25(OH)-vitamin D status: study of 1326 cases from the UK Biobank. *J Public Health (Oxf).* 2020; 42(3):451-460. https://doi.org/10.1093/pubmed/fdaa095
11. Huo L, Xu KL, Wang H. Clinical features of SARS-CoV-2-associated encephalitis and meningitis amid COVID-19 pandemic. *World J Clin Cases.* 2021; 9(5):1058-1078. https://doi.org/10.12998/wjcc.v9.i5.1058
12. Biswas S, Ghosh R, Mandal A, Pandit A, Roy D, Sengupta S, De K, Swaika BC, Benito-León J. COVID-19 Induced Miller Fisher Syndrome Presenting With Autonomic Dysfunction: A Unique Case Report and Review of Literature. *Neurohospitalist*. 2022; 12(1):111-116. https://doi.org/10.1177/19418744211016709
13. Keyhanian K, Umeton RP, Mohit B, Davoudi V, Hajighasemi F, Ghasemi M. SARS-CoV-2 and nervous system: From pathogenesis to clinical manifestation. *J Neuroimmunol.* 2020; 350:577436. https://doi.org/10.1016/j.jneuroim.2020.577436
14. Moriguchi T, Harii N, Goto J, Harada D, Sugawara H, Takamino J, Ueno M, Sakata H, Kondo K, Myose N, Nakao A, Takeda M, Haro H, Inoue O, Suzuki-Inoue K, Kubokawa K, Ogihara S, Sasaki T, Kinouchi H, Kojin H, Ito M, Onishi H, Shimizu T, Sasaki Y, Enomoto N, Ishihara H, Furuya S, Yamamoto T, Shimada S. A first case of meningitis/encephalitis associated with SARS-Coronavirus-2. *Int J Infect Dis.* 2020; 94:55-58. https://doi.org/10.1016/j.ijid.2020.03.062
15. Almutairi MM, Sivandzade F, Albekairi TH, Alqahtani F, Cucullo L. Neuroinflammation and Its Impact on the Pathogenesis of COVID-19. *Front Med (Lausanne).* 2021; 8:745789. https://doi.org/10.3389/fmed.2021.745789
16. Acharya A, Kevadiya BD, Gendelman HE, Byrareddy SN. SARS-CoV-2 Infection Leads to Neurological Dysfunction. *J Neuroimmune Pharmacol*. 2020; 15(2):167-173. https://doi.org/10.1007/s11481-020-09924-9
17. Sher EK, Ćosović A, Džidić-Krivić A, Farhat EK, Pinjić E, Sher F. Covid-19 a triggering factor of autoimmune and multi-inflammatory diseases. *Life Sci.* 2023; 319:121531. https://doi.org/10.1016/j.lfs.2023.121531
18. Yaqoob A, Dar W, Khuja Z, Bukhari I, Raina A, Ganie H, Chandra A, Wani M, Asimi R, Wani F. Miller Fisher syndrome associated with COVID 19. *J Family Med Prim Care.* 2022; 11(7):4023-4025. https://doi.org/10.4103/jfmpc.jfmpc_1864_21
19. Faulkner L, Scott S, Flint N. Miller-Fisher syndrome associated with SARS-CoV-2: a case report. *Microbes Infect*. 2022; 24(5):104954. https://doi.org/10.1016/j.micinf.2022.104954

20. Montalvan V, Lee J, Bueso T, De Toledo J, Rivas K. Neurological manifestations of COVID-19 and other coronavirus infections: A systematic review. *Clin Neurol Neurosurg*. 2020; 194:105921. https://doi.org/10.1016/j.clineuro.2020.105921
21. Wu X, Wang Y, Xi ZQ. Clinical and antibodies analysis of anti-GQ1b antibody syndrome: a case series of 15 patients. *Acta Neurol Belg*. 2023; 123(3):839-847. https://doi.org/10.1007/s13760-022-01940-1
22. Noioso CM, Bevilacqua L, Acerra GM, Della Valle P, Serio M, Vinciguerra C, Piscosquito G, Toriello A, Barone P, Iovino A. Miller Fisher syndrome: an updated narrative review. *Front Neurol.* 2023; 14:1250774. https://doi.org/10.3389/fneur.2023.1250774
23. Leonhard SE, Mandarakas MR, Gondim FAA, Bateman K, Ferreira MLB, Cornblath DR, van Doorn PA, Dourado ME, Hughes RAC, Islam B, Kusunoki S, Pardo CA, Reisin R, Sejvar JJ, Shahrizaila N, Soares C, Umapathi T, Wang Y, Yiu EM, Willison HJ, Jacobs BC. Diagnosis and management of Guillain-Barré syndrome in ten steps. *Nat Rev Neurol.* 2019; 15(11):671-683. https://doi.org/10.1038/s41582-019-0250-9
24. Martins-Filho PR, Pereira de Andrade AL, Pereira de Andrade AJ, Moura da Silva MD, de Souza Araújo AA, Nunes PS, Santos VS, Ferreira LC, de Aquino Neves EL, Quintans-Júnior LJ. Miller Fisher Syndrome in Patients With Severe Acute Respiratory Syndrome Coronavirus 2 Infection: A Systematic Review. *J Clin Neurol.* 2021; 17(4):541-545. https://doi.org/10.3988/jcn.2021.17.4.541
25. Han MS, Um J, Lee EJ, Kim KM, Chang SH, Lee H, Kim YK, Choi YY, Cho EY, Kim DH, Choi JH, Lee J, Kim M, Chung KH, Min HS, Choe YJ, Lim DG, Park JS, Choi EH. Antibody Responses to SARS-CoV-2 in Children With COVID-19. *J Pediatric Infect Dis Soc.* 2022; 11(6):267-273. https://doi.org/10.1093/jpids/piac012
26. Shomuradova S S, & Aminova A A. Organization of early diagnosis and prevention of thymomegaly in children. *World Bulletin of Public Health*. 2023; 22:1-4. Retrieved from https://scholarexpress.net/index.php/wbph/article/view/2636
27. Jahangir M, Craig B, Raheleh A, Chapter 12 - Thymus Tumors, Epidemiology of Endocrine Tumors, *Elsevier*, 2020, Pages 283-294, ISBN 9780128221877.
28. Durmaz S C. Neurological Findings of COVID-19 in children and effects on children with neuromuscular disease. *Multidisciplinary Approaches To Covid-19*. 2022:127-137.