JOURNAL OF CLINICAL MEDICINE OF KAZAKHSTAN (E-ISSN 2313-1519)
Review Article DOI: https://doi.org/10.23950/jcmk/13329

Adnexal masses associated with pelvic pain: A review and commentary on the evidence

Juan Carlos Tirado-Tapia[1], Enrique Sanchez-Valdivieso[1,2]

[1]*Department of Oncology, High Specialty Hospital of Veracruz, Mexico*
[2]*Department of Research, School of Medicine, Cristobal Colon University, Veracruz, Mexico*

Received: 2023-04-14.
Accepted: 2023-05-23

J Clin Med Kaz 2023; 20(3):8-13

Corresponding author:
Enrique Sanchez-Valdivieso.
E-mail: easanchezv@gmail.com;
ORCID: 0000-0002-3609-8228

Abstract

Pain in relation to the menstrual cycle is representative of Endometriosis. It has been reported that Endometriosis can be easily confounded with neoplasia. In the clinical practice of Gynecologic Oncology we find with relative frequency patients who are unknown carriers of endometriosis who present and are operated on because they resemble a picture of gynecological cancer, predominantly of the ovary. It has been reported that Endometriosis can be easily confounded with neoplasia. Endometriomas form part of the differential diagnosis alongside various ovarian cystic formations.

On the other hand, ovarian tumors are very common in women of reproductive age. Most are benign, but malignant ovarian tumors are a leading cause of cancer death in women.

In women with endometriosis, the risk of developing ovarian cancer has been estimated to be up to 50% higher than in the general population. The aim of our concise review was to establish the current state of knowledge regarding adnexal tumors associated with pelvic pain.

Key words: endometrioma, tumor-associated pain, differential diagnosis

Introduction

Endometriosis affects approximately one in ten women at some point in their lives [1], mainly during reproductive age since it is an estrogen-dependent disease, and who will manifest pain in relation to their menstrual cycles, either as dyspareunia, dyschesia, dysmenorrhea or chronic pelvic pain with or without the presence of infertility. Different theories have been proposed regarding its pathogenesis.

Among the most accepted theories are the predisposition due to genetic factors, increased secretion of cytokines and other inflammatory mediators, in utero exposure to estrogens or potent environmental toxins, or the widely accepted retrograde menstruation secondary to subtle anatomical alterations. However, its appearance has been reported even among patients who underwent an adnexal-sparing hysterectomy or in Mayer-Rokitansky-Küster-Hauser syndrome [2] where there is congenital absence of the uterus as part of the syndromatic procession.

In our clinical practice of Gynecology Oncology we find with relative frequency patients who are unknown carriers of endometriosis who present and are operated on because they resemble a picture of gynecological cancer, predominantly of the ovary. It has been reported that Endometriosis can be easily confounded with neoplasia.

Therefore, the objective of our review presented here was to establish the current knowledge and intertwine the current state of the art with our experience in managing clinical situations regarding adnexal tumors associated with pelvic pain.

Ovarian endometriosis as a cause of pelvic pain

What is happening in endometriosis is that the endometrial tissue, both the stroma and glands, is actually located outside of the uterus. This entity can be detected clinically in approximately one in ten of patients during reproductive age, up to 50 % of them present infertility associated with chronic pelvic pain [3,4,5].

The incidence of endometriosis in infertile women is about 50% and it is estimated that around 190 million young women and adolescents worldwide suffer from the disease, although it can also occur in menopausal women [6]. As for adolescents diagnosed with endometriosis, it is estimated that 70-93% present some discomfort associated with menstruation, as well as being associated with a higher risk of depression and anxiety [7]; therefore, this condition affects the quality of life not only the woman who suffers it, but also the partner or relatives [6].

The appearance of endometriosis at earlier ages is associated with a delay in diagnosis [7]. The diagnosis is usually made 8-12 years on average from the onset of symptoms [6]. Therefore, it is of great importance for the clinician to keep in mind the prevalence of this disease as well as manage a high index of suspicion.

Ovarian endometriomas

Endometriosis can have different forms of clinical presentation [8]. The most common form of presentation in 20-25% of patients with endometriosis are ovarian cysts (endometriomas) [9]; ovarian endometriomas (OMAs) are associated with pain that usually goes from moderate to severe. However, severe pain may be associated with concomitant "deep infiltrating endometriosis" (DIE) [10].

Other forms of endometriosis are "superficial endometriosis" commonly found in the peritoneum, characterized by the endometrial tissue being found on the surface of the subserosal soft tissue of the peritoneum or visceral organs [3,8,11] or as "DIE" which measures more than 5mm [8,11] reaching the muscle layer and is commonly located in the recto-vaginal septum, bladder wall, diaphragm or other organs [3,11]; it usually causes significant pain and also gastrointestinal and/or urological abnormalities that do not respond to medical treatment, most cases ending in surgical management [3] (Figure 1).

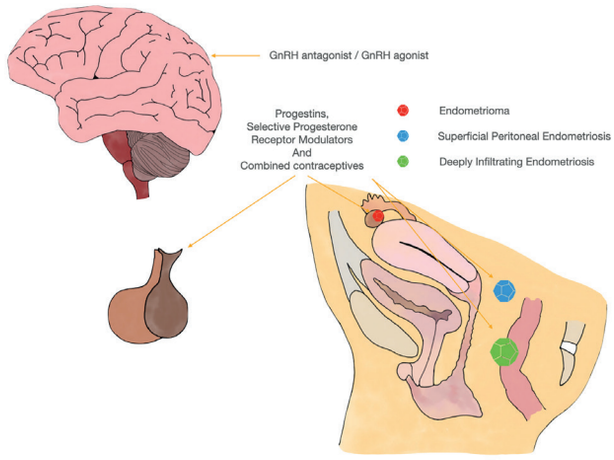

Figure 1 - The most common forms of endometriosis: The ovarian endometrial cyst (red mark) followed by superficial peritoneal endometriosis (blue mark) and deeply infiltrating endometriosis (green mark). GnRH agonist/antagonist exert an effect over the CNS. Progestins, SPRMs and combined contraceptives exert an effect over the hypophysis and directly over the endometrial lesions.

Endometriosis-associated risk factors

There are some risk factors that have been related to the disease, including genetic factors (family history), exposure to endogenous estrogens for long time, as happens with early menarche, late menopause and short menstrual cycles, heavy menstrual bleeding, outflow tract obstruction (Müllerian alterations) and exposure to to diethylstilbestrol in utero [5,7]. It is believed that among the genetic factors, chromosomal alterations in 7p15.2 and 10q26 may be involved, as well as the ARID1A and PIK3CA genes in ovarian cancer in patients with endometrial ovarian cysts [8].

Causes of endometriosis

There have been proposed some theories as cause of endometriosis, like Samson's theory, which consists of a retrograde menstruation, that is, menstrual bleeding that can reach the peritoneal cavity after passing through the tubes; however, 90% of normal women may present retrograde menstruation without problems [5]. More recent studies have shown that endocrine, immunological, pro-inflammatory and pro-angiogenic processes must be present concomitantly with retrograde menstruation [8] The GE theory (genetic and epigenetic changes) suggests that a series of GE changes can occur during cell division, causing the endometrial tissue to develop characteristics of cancer cells [12]. Another theory includes the generation of a coelomic metaplasia in which there is a transformation of the mesothelium to a glandular endometrium or lymphatic or hematogenous metastasis [8].

The reflux of endometrial tissue by itself contributes to the progress of pain and development of infertility; for the evolution of OMAs the presence of hormonal fluctuations and ovulation during menstruation are essential [10]. The endometrial tissue forms an ovarian cyst in the ovary that gives rise to a hematoma [5]. The formation of endometrioma causes ovarian reserve levels to decrease and favor the adhesions between the tubes and the broad ligament with the ovary [9]. Ectopic endometrial tissue results in inflammation which causes or promotes pain, dyspareunia, dysmenorrhea, and infertility [5].

Symptoms of endometriosis

The most common reported symptom among patients with endometriosis is dysmenorrhea. This symptom is the result of the prostaglandin production within the pelvic cavity, which causes endometrial hypertonia and secondary ischemia [10]; in a third of cases, ovarian endometriosis is bilateral [5]. The ectopic endometrium causes a chronic estrogen-dependent inflammatory reaction, triggering pain secondary to compression of the adjacent nerves and/or an increase in the prostaglandin production [7]. We can find in the peritoneal fluid of patients with endometriosis the presence of IL-10, IL-6, IL-8, COX-2, VEGF and TNF-α [13].

Characteristically, endometrial lesions have an increased expression of ER beta, which promotes the growth of lesions by inhibition of TNF-alpha by increasing interleukin Iß which improves cell adhesion and proliferation [8]; high levels of estradiol in turn causes PR to decrease [14]. Type A and B PR change during the menstrual cycle in response to the variation of ovarian steroids, their maximum expression occurs in the middle of the cycle [15]. Progesterone triggers the PR beta during the luteal phase, which promotes the transcription of the 17-ß-hydroxysteroid dehydrogenase (17ß-HSD) -2, which transforms estradiol-E2 into E1, which is a less potent form of estradiol [14,16]. However, ectopic endometrial tissue has an ER-alpha lower expression, and increased ER-beta, compared to the endometrium [16]; instead, PR expression may be decreased or even absent [17], which gives rise to resistance to progesterone [16]. COX-2 and aromatase are also responsible for stimulating the synthesis of E2 [18].

Endometriosis-related pain

The characteristics of the pain depend on the location [19]. When endometriosis is found in the peritoneum or in the pelvic wall, the pain is usually of somatic type. Pain is usually more localized, supposedly because to the high density of sensory nerve fibers in the parietal peritoneum. Later, macrophages colonize the nerve fibers [8,20] increasing the intensity of pain [20]; these macrophages have an increased expression of IGF-1, which in endometrial cells prevents apoptosis, and in stromal cells increases the expression of the ER beta [21]. Patients with endometriosis present an increase in neurotransmission from the anterior insula to the medial prefrontal cortex, promoting chemical changes which alter brain functions, increasing pain intensity, and increasing the risk of cross-organ sensitization due to the convergence of neuronal pathways [8]; interestingly, this central sensitization effect may explain coexisting chronic syndromes, irritable bowel syndrome, bulbodynia, or painful bladder syndrome [10].

On the other hand, the pain is usually of visceral type when endometrial lesions are found in the uterus, bladder or intestine, making the pain less localized and more spasmodic [19]. "DIE" usually develops other symptoms depending on the site where the condition is found. For example, when the lesions are rectovaginal, it usually causes dyschetia, stool irregularities, and constipation; lesions located in the bladder usually cause cyclic dysuria or even hematuria when the urethra is involved and/or the bladder is infiltrated.

In women suffering from endometriosis, nerve growth factor (NGF) has been found elevated in the peritoneal fluid, which gives rise to acyclic neurological inflammation causing pain resistance to NSAID's and hormonal therapy that in the long term can generate depression and somatoform disorders [19].

Adnexal causes of pelvic pain

Endometriosis can occur during a woman's reproductive life as frequently as 5 to 15% [20]. When this common gynecological condition becomes symptomatic, it can manifest with chronic pelvic pain, dyspareunia, or dysmenorrhea [21]. Therefore, the appearance of any pelvic pain during reproductive life represents a significant diagnostic challenge.

The local inflammatory reaction caused by endometriotic implants triggers, in turn, formation of adhesions which will produce fibrosis and a modified pelvic anatomy. This progressive sequence of changes can lead to pelvic organ dysfunction, with the onset of infertility and chronic pelvic pain.

The most frequent location of endometriotic implants is the ovary. This diagnosis should be considered, along with cancer, cystadenomas, tuboovarian abscesses, hemorrhagic cysts, and cystic adenomyoma, within the differential diagnoses. Ultrasound is particularly useful for identifying the "typical" endometrioma in premenopausal women, as it can easily identify unilocular cysts with echogenicity of ground-glass content, poor vascularity on color Doppler evaluation, and debris/polar clots.

The clinical diagnosis, however, is sometimes not easy, particularly when there are multiple cysts, since they can make it difficult to distinguish the adnexal endometrioma from some different masses, as mucinous cystadenomas (Figure 2). When there is intracystic vascularization, its presence can lead the clinician to suspect the presence of cancer (endometrioid adenocarcinoma or a borderline tumor of the ovary) [22] since 1% of these masses presumably suspected as endometriomas will result in a clear neoplasia.

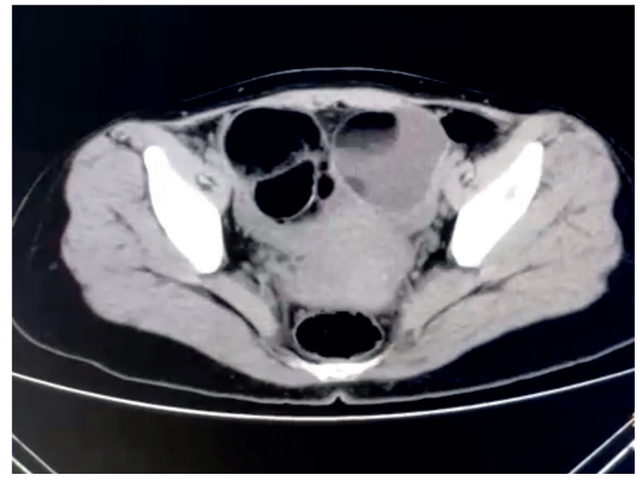

Figure 2A - Case of surgically and pathologically confirmed endometrioma. CT images showing a large lesion in the pelvis in which the significant perilesional inflammatory reaction is evident.

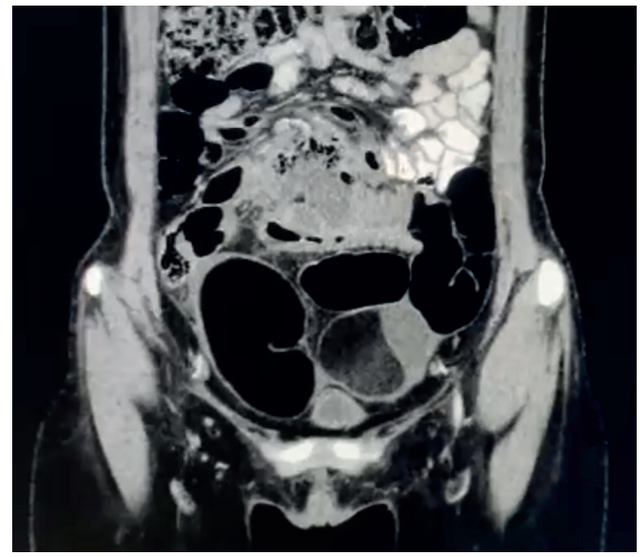

Figure 2B - Case of surgically and pathologically confirmed endometrioma. CT images showing a large lesion in the pelvis in which the significant perilesional inflammatory reaction is evident.

Pain evolution in endometriosis

The onset of pain is caused by biochemical signaling caused by the production of some pro-inflammatory molecules, as TNF-alpha, PGE2 and interleukin [8,10], which increase sensitivity and become a neuronal sign (peripheral sensations). This type of pain is usually well controlled with NSAIDs and hormonal therapy (by decreasing the release of inflammatory mediators) [19]. Estradiol has been identified as the main mediator of macrophages, as well as some chemoattractants such as IL-8, which causes neutrophil infiltration in the peritoneal fluid. It has been observed that macrophages invade the ectopic endometrium in greater numbers than the normal endometrium, activating NF-kB that promotes the expression of pro-inflammatory toxins and COX-9, which with the expression of pro-inflammatory cytokines such as IL-6, IL-1beta and TNF-alpha [23], stimulates cell proliferation, angiogenesis, inflammation and production of adhesion molecules of the endometrial tissue [13].

Bleeding within the pelvic cavity from the ectopic endometrial tissue trigger the secretion of pro-inflammatory and pro-oxidants factors, producing free iron and reactive oxygen

species (ROS) [11,16]. Iron overload activates the transcription of NF-kB in the endometrial stromal cells [11,24] causing overexpression of the divalent metal transporter I (DMTI), which promotes oxidative stress [24] giving rise to macromolecular oxidative damage [11]. In addition to this, oxidative stress and pro-inflammatory factors interrupt the function of PR, causing resistance to progesterone [16] and, concomitantly, there may be an alteration in the ROS elimination pathway, which increases chronic inflammation [11]. Adaptive immunological mechanisms are also involved in the development of pain. IL-10 has been identified in the peritoneal fluid, which has been related to an increase in the severity of the disease, and IL-17 is believed that contributes to the progression of endometriosis, as well as the stimulation of cytokines which induce angiogenesis and inflammation [23].

In severe dysmenorrhea, pain is initially regulated at the spinal level; however, in cyclic dysmenorrhea it triggers a process in which the release of neurotransmitters is altered, causing spinal hyperalgia [19]. Studies in mice with endometriosis have shown a significant increase in COX-2 and TNF-alpha in the spinal cord and brain [25] The pain can be so severe that can trigger vegetative reactions (nausea, vomiting), and patient adopts different positions in order to relieve pain. At the same time this can cause contraction of pelvic muscles which, in the long term, leads to dysfunction of the pelvic floor [19].

Overview of ovarian tumors

Ovarian tumors can frequently develop in women of reproductive age. Most are benign tumors, but malignancies are a leading cause of cancer death in women. Due to the complexity of the different tissues of origin, there is a variety of patterns and types of ovarian tumors, so most of the time a certain preoperative diagnosis will not be possible, except in very few patients. Screening among women with no family history, has not demonstrated an impact in the reduction of ovarian cancer mortality.

Most women with early-stage ovarian tumors are mainly asymptomatic; some other may experience mild gastrointestinal symptoms. In case of a palpable abdominal mass, patients frequently present other data such as ascites, pressure on pelvic or abdominal organs, and sometimes pain.

Ultrasound is useful for making a differential diagnosis of ovarian masses among themselves or with extraovarian masses, and between those that are benign and those that have a greater malignant potential. However, US has low sensitivity used as screening in the low-risk group of patients.

Once a pelvic mass is detected, it should first of all be categorized by the clinician. In terms of malignancies, the age of women is of crucial importance as a predictive factor, since in patients over 35 years of age the possibility of carrying a malignant epithelial tumor increases exponentially. In underage women, this possibility decreases enormously, being replaced by benign or borderline epithelial tumors, or by malignant tumors of germinal lineage, much rarer and that should receive conservative management.

Other relevant predictive factors to consider are ultrasound findings, serum CA 125 level, whether the ovarian mass is single or bilateral, its size, and whether or not there is pain. Simple cyst less than 8 cm in size is mostly benign, especially if accompanied by pain. Most ot these simple cysts will undergo regression and resolve spontaneously; they should be just monitored with no surgical intervention. If the mass is symptomatic, surgical exploration is warranted. Likewise, an invasive procedure should be indicated if the mass did not change in size on repeated ultrasound evaluation. A clear advantage of using transvaginal over abdominal ultrasound has not been demonstrated, but patient preference, especially the discomfort of bladder filling required for abdominal ultrasound, should always be an important consideration by the clinician.

If the mass is 10 cm in diameter or larger, a surgical procedure is warranted, especially if accompanied by pain. If the content of the cyst on ultrasound is considered hemorrhagic, with debris inside and is accompanied by significant abdominopelvic pain, especially cyclical, monthly repetitive, the diagnosis of endometrioma should be considered as a strong possibility, regardless of the data of suspicion of papillae or calcifications in the patient with less than 35 years, as well as a determination of serum CA 125 that reports levels < 200 units. In the case of a benign neoplasm, unilateral oophorectomy or even tumor excision is usually performed. If malignancy were suspected, the evaluation must be carried out by an oncologist.

For early stage ovarian cancer, you will have to decide the surgical approach depending on the patients' age. For patients over 35 years of age, the standard therapy should be surgical staging including hysterectomy and bilateral salpingo-oophorectomy with omentectomy, selective lymphadenectomy in some cases, and appendectomy in the case of mucinous tumors; all of this considering an epithelial ovarian cancer as the first possibility.

Aggressive removal of all visible tumor, seeking to achieve an optimal residual for intra-abdominal disease, would improve the survival in the case of more advanced disease. In these women, adjuvant or postoperative chemotherapy is indicated, especially the combination of Carboplatin with Paclitaxel, rescuing up to two thirds of these patients.

In the case of patients less than 35 years with a rare germline cancer, a conservative surgical management is imposed, respecting pelvic organs and fertility, with the administration of postoperative chemotherapy, which will be curative in these patients and will rescue the vast majority of women.

Endometriosis mimicking adnexal tumors

In our clinical practice of Gynecology Oncology not infrequently we find patients who are unknown carriers of endometriosis who present and are operated on because they resemble a picture of gynecological cancer, predominantly of the ovary. Endometriosis is often easily misdiagnosed as a malignancy [26].

In addition, the diagnosis of a pelvic neoformative process, particularly if it is a non-cystic malignancy, is favored by the macroscopic appearance of the lesion. These unusual cases represent greater difficulties in management even in experienced centres. The frozen-section pathological examination is a very useful intraoperative analysis that helps to make a surgical decision, increasing sensitivity and specificity for the risk classification [27].

In the differential diagnosis, neither the clinical presentation nor the age of presentation of endometriosis can be taken into account, which are largely similar to the other diagnoses.

The presentation of endometriosis is often retroperitoneal, close to the uterus (i.e., paracervical and parametrial) [28]. We have to include in the differential diagnosis the presence of a lateral spread of cervical cancer [29]. We have found endometrioid adenocarcinomas arising from an endometriotic cyst located in the broad lateral ligament, in proximity to the pelvic wall, in apposition to the ureter. Broad ligament endometriosis can also infiltrate medially into paracervical tissues, and in many cases even appear as a solid mass [30]. In contrast, frank retroperitoneal cystic endometriosis is not common [26].

Endometriosis-associated ovarian cancer

A 1.4 to 1.9% risk of developing ovarian cancer throughout life has been reported among patients with endometriosis, compared to the general population [31,32].

Epithelial ovarian cancer

Endometriosis is tightly related to some subtypes of epithelial ovarian cancer (EOC), particularly ovarian clear cell carcinoma (OCCC) and endometrioid ovarian carcinoma (EnOC) [33].

This association between endometriosis and EOC subtypes has been confirmed by detecting mutations in cancer-associated genes using molecular pathology [35,36]. The first time they were reported in the literature, in 1925, they were described as endometriosis-associated endometrioid ovarian carcinoma [34].

It is known that, despite this, patients with endometriosis will spend years suffering from this benign disease but will never develop cancer related to endometriosis; it is also known that OCCC and EnOC that can occur in younger women, most of them in the range between 35 and 55 years of age, are directly related to endometriosis. EnOC's constitute 10% of EOC's and, similarly, prevalence of OCCC's is between 5-12% [33].

Ovarian germ cell neoplasm

A less frequent group of malignant neoplasms, ovarian germ cell malignancies (OGCM's) most usually present in women under the age of 30. The most frequent symptom in this group of very low-incidence tumors is abdominal pain accompanied by a mass, abdominal or pelvic, in 85% [37]. The disease manifests clinically with pain as the first symptom in 64% of patients and abdominal distension as the first sign in 26% of cases [38]. Transvaginal bleeding and ascites are also reported. In a much smaller percentage of patients it can present acutely with symptoms due to ovarian torsion. The median age of OGCM patients at diagnosis is 24 years [38].

Definitive diagnosis

The definitive diagnosis depends to a great extent on the findings in the ultrasonogram (US). In this study, endometriomas are frequently observed as thick-walled unilocular masses with regular margins that are often bilateral and multiple, with homogeneous content and fine internal echoes that result in an echogenic "ground glass" appearance, caused by the blood cells flaking off the walls [39].

Ovarian endometriomas constitute an important differential diagnosis of a large number of ovarian cystic lesions such as benign cystic teratomas or dermoid cysts, and hemorrhagic luteal cysts. The US is important to detect the characteristics of the lesion, variable in each case. The edges may be serrated; they can be infiltrated by the surrounding tissues. Most disease deposits demonstrate vascularization on color Doppler.

In the absence of a conclusive US or with suspicion of ovarian cancer, a CAT or MRI scan is recommended [40]. Tumor markers must be interpreted in a prudent and judicious manner, maintaining an important consideration of the context, with the decision being made according to the age of the patient.

Conclusion

Benign or malignant tumors can resemble and be diagnosed as Ovarian Endometrioma. These cases represent greater difficulties in management even in experienced centres. The clinical presentation is generally not very helpful in the differential diagnosis. The intraoperative frozen-section analysis is of great help in making a surgical decision. Tumor markers must be interpreted in a prudent and judicious manner, maintaining an important consideration of the context, with the decision being made according to the age of the patient. In the case of a malignant neoplasm, it will always be recommended that the person responsible for performing the surgical evaluation and making the surgical decision be a gynecologic oncologist.

Disclosures: There is no conflict of interest for all authors.

Acknowledgements: None.

Funding: None.

References

1. Bulun SE. Endometriosis. *N Engl J Med.* 2009; 360:268-79. https://doi.org/10.1056/NEJMra0804690
2. Konrad L, Dietze R, Kudipudi PK, et al. Endometriosis in MRKH cases as a proof for the coelomic metaplasia hypothesis? *Reproduction*. 2019; 158:R41-7. https://doi.org/10.1530/REP-19-0106
3. Wang Y, Nicholes K, Shih I-M. The origin and pathogenesis of endometriosis. *Annu Rev Pathol*. 2020; 15:71-95. https://doi.org/10.1146/annurev-pathmechdis-012419-032654
4. Hayashi S, Nakamura T, Motooka Y, Ito F, Jiang L, Akatsuka S, Iwase A, Kajiyama H, Kikkawa F, Toyokuni S. Novel ovarian endometriosis model causes of infertility via iron-mediated oxidative stress in mice. *Redox Biol*. 2020; 37:101726. https://doi.org/10.1016/j.redox.2020.101726
5. Smolarz B, Szyłło K, Romanowicz H. Endometriosis: Epidemiology, Classification, Pathogenesis, Treatment and Genetics (Review of Literature). *Int J Mol Sci*. 2021; 22(19):10554. https://doi.org/10.3390/ijms221910554
6. Becker CM, Bokor A, Heikinheimo O, Horne A, Jansen F, Kiesel L, King K, Kvaskoff M, Nap A, Petersen K, et al. ESHRE guideline: endometriosis. *Human Reproduction Open.* 2022; 2022(2): hoac009
7. Sachedina A, Todd N. Dysmenorrhea, Endometriosis and Chronic Pelvic Pain in Adolescents. *J Clin Res Pediatr Endocrinol.* 2020; 12(Suppl 1):7-17. https://doi.org/10.4274/jcrpe.galenos.2019.2019.S0217
8. Zondervan KT, Becker CM, Missmer SA. Endometriosis. *N Engl J Med.* 2020; 382(13):1244-1256. https://doi.org/10.1056/NEJMra1810764
9. Nowak-Psiorz I, Ciećwież SM, Brodowska A, Starczewski A. Treatment of ovarian endometrial cysts in the context of recurrence and fertility. *Adv Clin Exp Med.* 2019; 28(3):407-413. https://doi.org/10.17219/acem/90767
10. Chapron C, Marcellin L, Borghese B, Santulli P. Rethinking mechanisms, diagnosis and management of endometriosis. *Nat Rev Endocrinol.* 2019; 15(11): 666-682. https://doi.org/10.1038/s41574-019-0245-z
11. Cacciottola C, Donnez J, Dolmans M-M. Can Endometriosis-Related Oxidative Stress Pave the Way for New Treatment Targets? *Int J Mol Sci*. 2021; 22(13):7138. https://doi.org/10.3390/ijms22137138

12. Koninckx PR, Fernandes R, Ussia A, Schindler L, Wattiez A, Al-Suwaidi S, Amro B, Al-Maamari B, Hakim Z, Tahlak M. Pathogenesis Based Diagnosis and Treatment of Endometriosis. *Front Endocrinol (Lausanne)*. 2021; 12:745548. https://doi.org/10.3389/fendo.2021.745548
13. Vallée A, Lecarpentier Y. Curcumin and Endometriosis. *Int J Mol Sci.* 2020; 21(7):2440. https://doi.org/10.3390/ijms21072440
14. Sroyrayaa M, Songkoomkronga S, Changklungmoac N, Poljaroena J, Weerakietd S, Sophonsritsukd A, Wongkularbd A, Lertvikoold S, Tingthanatikuld Y, Sobhon P. Differential expressions of estrogen and progesterone receptors in endometria and cyst walls of ovarian endometrioma from women with endometriosis and their responses to depo-medroxyprogesterone acetate treatment. *Mol Cell Probes*. 2018; 40:27-36. https://doi.org/10.1016/j.mcp.2018.07.001
15. Reis FM, Coutinho LM, Vannuccini S, Batteux F, Chapron C, Petraglia F. Progesterone receptor ligands for the treatment of endometriosis: the mechanisms behind therapeutic success and failure. *Hum Reprod Update.* 2020; 26(4):565-585. https://doi.org/10.1093/humupd/dmaa009
16. Donnez J, Dolmans MM. Endometriosis and Medical Therapy: From Progestogens to Progesterone Resistance to GnRH Antagonists. *J Clin Med.* 2021; 10(5):1085. https://doi.org/10.3390/jcm10051085
17. Fu J, Song H, Zhou M, Zhu H, Wang Y, Chen H, Huang W. Progesterone receptor modulators for endometriosis. *Cochrane Database Syst Rev.* 2017; 7(7):CD009881. https://doi.org/10.1002/14651858.CD009881.pub2
18. Wan Hung S, Zhang R, Tan Z, Pui Wah Chung J, Zhang T, Wang CC. Pharmaceuticals targeting signaling pathways of endometriosis as potential new medical treatment: A review. *Med Res Rev.* 2021; 41(4):2489-2564. https://doi.org/10.1002/med.21802
19. Gruber TM, Mechsner S. Pathogenesis of Endometriosis: The Origin of Pain and Subfertility. *Cells*. 2021; 10(6):1381. https://doi.org/10.3390/cells10061381
20. Zondervan KT, Becker CM, Missmer SA. Endometriosis. N Engl J Med. 2020; 382:1244-1256. https://doi.org/10.1056/NEJMra1810764
21. Mehedintu C, Plotogea MN, Ionescu S, Antonovici M. Endometriosis still a challenge. *J Med Life.* 2014; 7:349-357.
22. Moro F, Zannoni GF, Arciuolo D, Pasciuto T, Amoroso S, Mascilini F, Mainenti S, Scambia G, Testa AC. Imaging in gynecological disease (II): Clinical and ultrasound features of mucinous ovarian tumors. *Ultrasound Obstet Gynecol* 2017; 50:261-270. https://doi.org/10.1002/uog.17222
23. Symons LK, Miller JE, Kay VR, Marks RM, Liblik K, Koti M, Tayade C. The Immunopathophysiology of Endometriosis. *Trends Mol Med.* 2018; 24(9):748-762. https://doi.org/10.1016/j.molmed.2018.07.004
24. Li Y, Zeng X, Lu D, Yin M, Shan M, Gao Y. Erastin induces ferroptosis via ferroportin-mediated iron accumulation in endometriosis. *Hum Reprod.* 2021; 36(4):951-964. https://doi.org/10.1093/humrep/deaa363
25. Forster F, Sarginson A, Velichkova A, Hogg C, Dorning A, Horne AW, Saunders FTK, Greaves E. Macrophage-derived insulin-like growth factor-1 is a key neurotrophic and nerve-sensitizing factor in pain associated with endometriosis. *FASEB J*. 2019; 33(10):11210-11222. https://doi.org/10.1096/fj.201900797R
26. Reis-de-Carvalho C, Castro C, Osório F. Unusual endometriosis mimicking disseminated cancer after hysterectomy in a young woman. BMJ Case Rep. 2021; 14:e241002. https://doi.org/10.1136/bcr-2020-241002
27. Santoro A, Piermattei A, Inzani F, et al. Frozen section accurately allows pathological characterization of endometrial cancer in patients with a preoperative ambiguous or inconclusive diagnoses: our experience. *BMC Cancer.* 2019; 19:6. https://doi.org/10.1186/s12885-019-6318-5
28. Chiantera V, Petrillo M, Abesadze E, Sozzi G, Dessole M, Catello Di Donna M, Scambia G, Sehouli J, Mechsner S. Laparoscopic Neuronavigation for Deep Lateral Pelvic Endometriosis: Clinical and Surgical Implications. *J Minim Invasive Gynecol*. 2018; 25:1217-1223. https://doi.org/10.1016/j.jmig.2018.02.015
29. Alcazar JL, García E, Machuca M, Quintana R, Escrig J, Chacón E, Mínguez JA, Chiva L. Magnetic resonance imaging and ultrasound for assessing parametrial infiltration in cervical cancer. A systematic review and meta-analysis. *Med Ultrason*. 2020; 22:85-91. https://doi.org/10.11152/mu-2361
30. Leonardi M, Martins WP, Espada M, Arianayagam M, Condous G. Proposed technique to visualize and classify uterosacral ligament deep endometriosis with and without infiltration into parametrium or torus uterinus. *Ultrasound Obstet Gynecol.* 2020; 55:137-139. https://doi.org/10.1002/uog.20300
31. Vercellini P, Vigano P, Buggio L, et al. Perimenopausal management of ovarian endometriosis and associated cancer risk: When is medical or surgical treatment indicated? *Best Pract Res Clin Obstet Gynaecol.* 2018; 51:151-68. https://doi.org/10.1016/j.bpobgyn.2018.01.017
32. Somigliana E, Vigano' P, Parazzini F, et al. Association between endometriosis and cancer: a comprehensive review and a critical analysis of clinical and epidemiological evidence. *Gynecol Oncol*. 2006; 101: 331-41. https://doi.org/10.1016/j.ygyno.2005.11.033
33. Samartzis EP, Labidi-Galy SI, Moschetta M, Uccello M, Kalaitzopoulos DR, Perez-Fidalgo JA, Boussios S. Endometriosis-associated ovarian carcinomas: Insights into pathogenesis, diagnostics, and therapeutic targets - a narrative review. *Ann Transl Med*. 2020; 8:1712. https://doi.org/10.21037/atm-20-3022a
34. Sampson JA. Endometrial carcinoma of the ovary, arising in endometrial tissue in that organ. *Arch Surg.* 1925; 10: 1-72. https://doi.org/10.1001/archsurg.1925.01120100007001
35. Wiegand KC, Shah SP, Al-Agha OM, et al. ARID1A mutations in endometriosis-associated ovarian carcinomas. *N Engl J Med*. 2010; 363:1532-43. https://doi.org/10.1056/NEJMoa1008433
36. Jones S, Wang TL, Shih Ie M, et al. Frequent mutations of chromatin remodeling gene ARID1A in ovarian clear cell carcinoma. *Science*. 2010; 330:228-31. https://doi.org/10.1126/science.1196333
37. Baljeet K. Pathology of malignant ovarian germ cell tumours. *Diagnostic Histopathology.* 2020; 26(6):289-297. https://doi.org/10.1016/j.mpdhp.2020.03.006
38. Dellino M, Silvestris E, Loizzi V, Paradiso A, Loiacono R, Minoia C, Daniele A, Cormio G. Germinal ovarian tumors in reproductive age women: Fertility-sparing and outcome. *Medicine*. 2020; 99(39):e22146. https://doi.org/10.1097/MD.0000000000022146
39. Di Serafino M, Iacobellis F, Schillirò ML, Verde F, Grimaldi D, Dell'Aversano Orabona G, Caruso M, Sabatino V, Rinaldo C, Cantisani V, et al. Pelvic Pain in Reproductive Age: US Findings. *Diagnostics*. 2022; 12:939. https://doi.org/10.3390/diagnostics12040939
40. Piessens S, Edwards A. Sonographic Evaluation for Endometriosis in Routine Pelvic Ultrasound. *J Minim Invasive Gynecol*. 2020; 27:265-266. https://doi.org/10.1016/j.jmig.2019.08.027