JOURNAL OF CLINICAL MEDICINE OF KAZAKHSTAN (E-ISSN 2313-1519)
Case Report DOI: https://doi.org/10.23950/jcmk/13486

Clinical heterogeneity in Fabry disease: A clinical case

Assel Issabekova[1], Olga Mashkunova[2]

[1]*Cardiology Department, Scientific Institution of Cardiology and Internal Diseases, Almaty, Kazakhstan*
[2]*Therapeutic Department, National Medical University, Almaty, Kazakhstan*

Received: 2022-03-17.
Accepted: 2023-06-30

J Clin Med Kaz 2023; 20(4):68-70

Corresponding author:
Assel Issabekova.
E-mail: isabekova.ah@mail.ru;
ORCID: 0000-0002-3172-3610

Abstract

Fabry disease is an orphan lysosomal storage disease characterized by progressive organ damage. Considering that the disease is rare, the low awareness of doctors about this pathology leads to late diagnosis of the disease and untimely pathogenetic therapy. Clinical case of late (relative to clinical manifestation) diagnosis of the “classical” phenotype of Fabry Disease in a male patient with cardiac and renal damage and typical early presentations such as neuropathic pain, angiokeratomas, hypohidrosis.

Key words: Fabry disease, α-galactosidase, globotriaosylceramide, agalsidase

Introduction

Over the past 20 years, there has been a scientific advance in the study of orphan (rare) diseases. Genetic diagnosis and enzyme replacement therapy have reached a new level. There are around 8,000 rare diseases worldwide. The most common are sphingolipid lysosomal storage diseases (LSDs), one of which is Fabry disease (FD). Fabry disease is inherited recessively as an X-linked disorder, so the clinical signs are more frequent and earlier in males than in females [1]. Impaired sphingolipid metabolism is associated with a GLA (α-Galactosidase A) gene mutation and disruption of the α-galactosidase enzyme synthesis, which is required for their cleavage. As a result of insufficient α-Gal A production, metabolic products accumulate in organs and tissues in the form of globotriaosylceramide, which accumulates in the vascular endothelium, smooth muscle cells, neural cells, ganglia, renal podocytes, mesangial and tubular cells, cardiac muscle and cells of the cardiac conduction system.

The spectrum of clinical manifestations is highly heterogeneous, even in members of the same family [2]. The prevalence of the clinical phenotype depends on the type of GLA gene mutation, but nevertheless, the main and most characteristic manifestations are damage to vital systems: cardiovascular, urinary and nervous systems, which determine the severity and prognosis of the disease. Manifestation can start with any leading syndrome, evolving into classical or atypical "monosyndromic" forms [3,4].

Fabry disease can be divided into three clinical phenotypes related to α-Gal A activity levels. The first is the "classical" FD (α-Gal A<3% or absent enzymatic activity, onset in childhood or puberty, multisystem involvement including acroparesthesias, angiokeratomas, sweating abnormalities, gastrointestinal symptoms, cornea verticillata, hearing disorders. Long–term disease manifestations include progressive renal failure and cardiovascular events (third decade of life). The second is "nonclassical" FD, also referred to as late-onset or atypical FD (α-Gal A activity 3-30%, disease manifestations may be limited to a single organ: brain, heart or kidney); and the third is asymptomatic female carrier (in women with a mutation in only one X chromosome, the other continues to secrete α-Gal A, which can present clinically as a less severe or asymptomatic disease) [5,6].

The aim of our publication is to describe a case of delayed diagnosis of a classical Fabry disease with a predominance of cardiovascular and urinary system involvement in order to highlight the problem of early detection of an orphan disease, Fabry disease, among doctors of different specialties.

Case presentation

Patient S, born in 1994 (age 27) in May 2021 was diagnosed with chronic nephrotic syndrome. Stage G4A3 CKD (Chronic Kidney Disease), GFR (Glomerular Filtration Rate) -25 mL/min/1.73 m2.

Presenting complaints: muscle weakness, performance impairment a month earlier after hypothermia which first changed the urine colour to red, increased blood pressure.

At physical examination there was a haemorrhagic rash on the lower half of the body, around the navel and in the groin area (Figure 1).

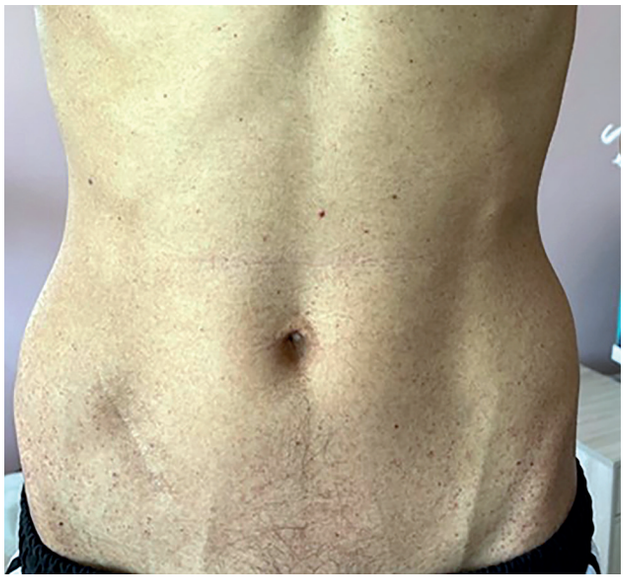

Figure 1 - Anterior abdominal wall angiokeratomas in the periumbilical area in patient S.

During the current visit the history of the present condition was clarified. Since the age of 6 years (2000) single angiokeratomas appeared in the umbilical region (angiokeratoma corporis diffusum); by the age of 16 years (2010) the rash had spread to the lumbosacral, buttocks and groin area. Associated with angiokeratomas at about the same period, the patient experienced burning pains in hands and feet occasionally with physical exertion and unexplained annual episodes of fever rising to 38-39° C, intensity of pains became less at the age of 14-15 years. A careful questioning of the patient revealed that he has a poor tolerance to heat and hardly ever sweats.

At the age of 27 (2021) he was diagnosed with nephritic syndrome, stage G4A3 CKD (GFR 25 mL/min/1.73 m2) and referred to the "Research Institute of Cardiology and Internal Medicine" for diagnosis verification. Fabry disease was suspected and tests were taken. Enzyme assay test results showed a decrease in α-Gal activity <0.8 μmol/L/h (reference, ≥ 15.0 μmol/L/h) and an increase in lyso-GL-3 levels up to 62 ng/mL (reference, ≤1.8 ng/mL).

This patient was tested positive for the hemizygous GLA mutation (NM_000169.2:c.679C>T (p.Arg227*) in a molecular genetic analysis.

From the family history, it is known that the patient's brother has a similar clinical presentation and his sister has minimal clinical symptoms. The defective gene (the GLA gene) has been inherited from the mother.

On further examination at the Research Institute of Cardiology and Internal Medicine the patient was diagnosed with a cardiac defect. Electrocardiography (ECG): sinus rhythm with a heart rate of 90 bpm; signs of left ventricular (LV) hypertrophy (Figure 2).

Electrocardiographic (ECG) changes characteristic of Fabry Disease were found: LVH, LV posterior wall thickness at end-diastole (LVPWTd) was 13mm, interventricular septal

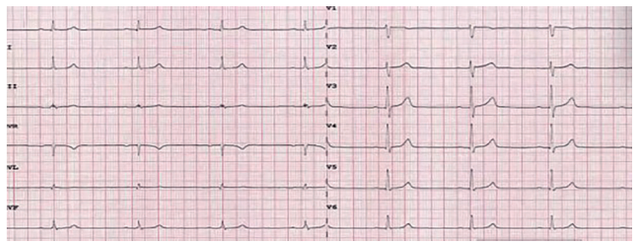

Figure 2 - ECG findings of patient S.: sinus rhythm, 90 bpm; leads V2-V6, signs of left ventricular myocardial hypertrophy. PR Interval: 0.13 sec, QRS Duration: 0.06 sec, QT Interval (QTc 0.36 sec)

thickness at end-diastole (IVSTd) was 13mm, MMI 127g/m2 (Figure 3). No reduction in global left ventricular contractility EF (Ejection Fraction), 60%; biplane Simpson's method), no regional wall motion abnormalities and no signs of ventricular diastolic dysfunction; large vessels, valve system and pericardium - no abnormalities.

Doppler echocardiography: mild (grade 1) mitral regurgitation, grade I tricuspid regurgitation. Pulmonary artery pressure was unchanged (17 mmHg). The examination revealed increased myocardial echogenicity.

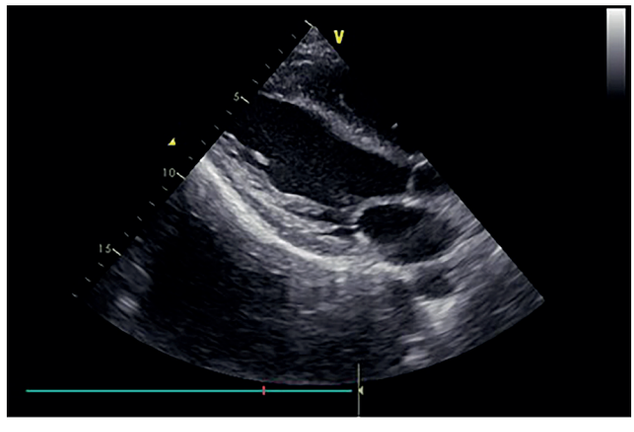

Figure 3 - TTE findings in patient S: left ventricular free wall hypertrophy

Holter ECG monitoring detected a small number of atrial premature beats, while 24-hour ambulatory blood pressure monitoring showed no evidence of hypertension.

Particular attention should be focused on renal impairment; this patient has stage G4A3 CKD (GFR 18 mL/min/1.73 m2). It should be noted that impaired renal function, up to dialysis-dependent chronic kidney disease (CKD C5d), is observed in the majority of patients with Fabry disease, making it highly suspicious in patients with CKD, especially those younger than 40 years and with morphologically unverified renal pathology [7]. In our case, the diagnosis was verified in the pre-dialysis period, which is certainly a favourable factor in our patient's treatment and prognosis.

The patient was diagnosed with Fabry disease at the age of 27 years following follow-up examination. He developed polyorganic lesions: skin lesions (angiokeratomas), peripheral nervous system lesions (peripheral neuropathy), exocrine gland dysfunction (hypohidrosis), kidney failure (CKD G4A3), cardiac damage (left ventricular hypertrophy). Inpatient enzyme replacement therapy with agalsidase alfa at a dose of 0.2 mg/kg body weight was carried out.

Discussion

Factors such as the non-specificity of most of the symptoms of Fabry disease, the difficulty of diagnosis and differential diagnosis, and the low awareness of the characteristic symptoms, mean that the disease is rarely detected de novo in the early stages. Screening is often most effective in high-risk groups, in particular in patients already receiving renal replacement therapy due to irreversible loss of renal function, early stroke survivors and patients with severe left ventricular hypertrophy. According to the Ricardo Reisin et al (2017) study, based on analysis of data from the international long-term observational registry (Fabry Outcome Survey (FOS)), in Europe and other countries the period from symptom onset to confirmation of diagnosis of FD in adults is 8 to 13 years (median 10.5 years), the period from diagnosis to initiation of enzyme replacement therapy is 0.9 to 1.1 years (median 1.1 year) [8]. Unfortunately, even in the presence of typical symptoms, the diagnosis of Fabry disease is often delayed, as in our clinical case of the **"classical" variant of FD** in a patient with polyorganic involvement (skin, peripheral nervous system, exocrine glands, kidneys and heart) and the initiation **of enzyme replacement therapy 21** years after the clinical manifestations. The onset of the disease presented with the rather characteristic symptoms of Fabry disease (peripheral polyneuropathy, angiokeratomas, hypohidrosis). In this case, the most important symptom causing the patient's discomfort was peripheral neuropathy, most likely considered to be Raynaud's syndrome, rheumatoid arthritis [9]. The decrease in pain intensity in our patient at age 14-15 years may be related to the period of puberty, when pain syndrome may be less pronounced or absent [10], due to progressive degeneration of nerve fibres [11,12]. Further involvement of the vital urinary system (stage G4A3) prompted referral to our hospital, where further examination revealed cardiovascular pathology (left ventricular hypertrophy) and the diagnosis was confirmed. In our case the diagnosis was established in the pre-dialysis period, which is clearly a favourable aspect of the treatment and prognosis of our patient. Immediate enzyme replacement therapy has been administered in order to reduce the progression of the disease [13].

Disclosures: There is no conflict of interest for all authors.

Acknowledgements: None.

Funding: None.

Patient informed consent: Obtained.

References

1. Vedder A. C., Strijland A., vd Bergh Weerman M. A., Florquin S., Aerts J. M., Hollak C. E. Manifestations of Fabry disease in placental tissue. *J. Inherit. Metab. Dis.* 2006; 29: 106–111. https://doi.org/10.1007/s10545-006-0196-0
2. Redonnet-Vernhet I., Ploos van Amstel J.K.,Jansen R.P., R A Wevers, R Salvayre, T Levade. Uneven X inactivation in a female monozygotic twin pair with Fabry disease and discordant expression of a novel mutation in the alphagalactosidase A gene. *J Med Genet*. 1996; 33:682–8. https://doi.org/10.1136/jmg.33.8.682
3. Spada M., Pagliardini S., Yasuda M., Tukel T., Thiagarajan G., Sakuraba H., Ponzone A., Desnick R. J. High incidence of later-onset fabry disease revealed by newborn screening. *Am. J. Hum. Genet.* 2006; 79: 31–40. https://doi.org/10.1086/504601
4. Hoffmann B., Beck M., Sunder-Plassmann G., Borsini W., Ricci R., Mehta A. Nature and prevalence of pain in Fabry disease and its response to enzyme replacement therapy — a retrospective analysis from the Fabry Outcome Survey. *Clin J. Pain*. 2007; 23. https://doi.org/10.1097/AJP.0b013e318074c986
5. Arends M, Wanner C, Hughes D, et al. Characterization of classical and nonclassicalFabry disease: a multicenterstudy. *J Am SocNephrol*. 2017; 28:16-31.
6. Michaud M, Mauhin W, Belmatoug N, et al. When and how to diagnose Fabry disease in clinical practice. *Am J Med Sci.* 2020; 3:1-9.
7. A.Ortiz, B.Cianciaruso, M. Cizmarik, Dominique P. Germain, R. Mignani, João Paulo Oliveira, J. Villalobos, B. Vujkovac, S. Waldek, Ch. Wanner. End-stage renal disease in patients with Fabry disease: natural history data from the Fabry Registry. *Nephrol Dial Transplant.* 2010; 25:769-775. https://doi.org/10.1093/ndt/gfp554
8. Reisin R, Perrin A, García-Pavía P. Time delays in the diagnosis and treatment of Fabry disease. *Int J ClinPract.* 2017; 71(1):e12914. https://doi.org/10.1111/ijcp.12914
9. Novikov P.V., Asanov A. Yu., Kopishinskaya S.V. Federal clinical guidelines for the diagnosis and treatment of Fabry disease. M.; 2013 (in Russian).
10. Úçeyler N., Ganendiran S., Kramer D., Sommer C. Characterization of pain in Fabry disease. *Clin J Pain.* 2014; 30:915–920. https://doi.org/10.1097/AJP.0000000000000041
11. Laaksonen S.M., Roytt S.K., Kantola I. Et al. Neuropathic symptoms and findings in women with Fabry disease. *ClinNeurophysiol.* 2008; 119:1365–1372. https://doi.org/10.1016/j.clinph.2008.02.004
12. Ghali J., Murugasu A., Day T., Nicholls K. Carpal tunnel syndrome in Fabry disease. *JIMD Rep*. 2012; 2:17–23. https://doi.org/10.1007/8904_2011_37
13. Ortiz A, Germain GP, Desnick RJ, Politei J ., Mauer M., Burlina A., Eng C., Hopkin R., Laney D, Linhart A., 10, Waldek S., Wallace E., Weidemann F., William R. Fabry disease revisited: management and treatment recommendations for adult patients. Mol Genet. *Metab*. 2018; 123(4):416-27. https://doi.org/10.1016/j.ymgme.2018.02.014