JOURNAL OF CLINICAL MEDICINE OF KAZAKHSTAN (E-ISSN 2313-1519)
Original Article DOI: https://doi.org/10.23950/jcmk/13357

Evaluation of the functional outcome following endoscopic decompression of retrocalcaneal bursitis

Simarjot Singh Sodhi, Rajesh Kumar Chopra, Jatin Prakash, Ashish Jaiman

Department of Orthopaedics, Central Institute of Orthopaedics, Vardhman Mahavir Medical College & Safdarjung Hospital, New Delhi, India

Received: 2023-03-31.
Accepted: 2023-05-23

J Clin Med Kaz 2023; 20(3):94-98

Corresponding author:
Ashish Jaiman.
E-mail: drashishjaiman@gmail.com;
ORCID: 0000-0002-4625-0107

Abstract

Introduction: Retro calcaneal bursitis is an inflammation of the bursa located between the posterior surface of the heel bone and the anterior surface of the Achilles tendon. This study was conducted to evaluate the clinical efficacy of endoscopic decompression and debridement in patients with retrocalcaneal bursitis who had not responded to conservative treatment. Our primary objective was to estimate the improvement in American Orthopaedic Foot and Ankle Society (AOFAS) score after surgery, and our secondary objectives were to estimate the average surgical duration and the incidence of post-operative complications.

Material and methods: This was a single-centre intervention study at a tertiary institution's level. Included in the study were all patients who were diagnosed with retrocalcaneal bursitis and who had failed a minimum 6-month trial of conservative treatment. 36 patients (36 heels) underwent endoscopic decompression.

Results: A prospective interventional cohort study was conducted on a total of 36 adult patients (18-70 years) with clinical and radiological findings suggestive of retrocalcaneal bursitis, duration of failed conservative treatment prior to surgery > 6 months, and refractoriness to other forms of non-operative treatment like steroid injections regardless of duration. There were no patients lost to follow-up. The mean duration of follow-up was 6 months [6 months to 2 years]. The average pre-operative AOFAS score was 56.42±6.8, ranging from 44 to 70. The difference between preoperative and postoperative AOFAS scores at 1 week, 2 weeks, 4 weeks, 3 months, and 6 months was statistically significant (p=0.0001).

Conclusion: In patients with retrocalcaneal bursitis, arthroscopic decompression is a safe, effective, and simple procedure. Within the first three months, the majority of study participants experienced pain relief and a significant improvement in function.

Key words: retrocalcaneal bursitis, endoscopic decompression, tendo-achilles, tendinitis

Introduction

Retrocalcaneal bursitis is an inflammation of the bursa between the posterior surface of the calcaneus and the anterior surface of the Achilles tendon [1]. The retrocalcaneal bursa is a horseshoe-shaped structure located above and behind the calcaneus [2]. Inflation of this bursa is most frequently associated with excessive prominence of the posterosuperior aspect of the calcaneum, which impinges on the Achilles tendon; this condition was first described by Haglund and is named after him [3]. The most prevalent etiological factors associated with Haglund deformity [4] are repetitive trauma, overuse, and pressure on the area caused by wearing tight-fitting shoes and high heels. Retrocalcaneal bursitis is also associated with gout, rheumatoid arthritis, and other spondyloarthropathies [5,6]. Bursitis typically results in insertional Achilles tendinitis, which is the degeneration of the distal 2 cm of Achilles tendon from its insertion over the calcaneus

[7]. Retrocalcaneal bursitis causes pain and discomfort among patients in posterior part of heel and is usually diagnosed is usually by the lateral view radiograph of the ankle joint that may show postero-superior bony prominence and intra tendinous calcification [3,8]. Ultrasound and MRI are additional imaging methods used to confirm the diagnosis [3]. Conservative treatment, including footwear modification, the use of heel pads, moist heat, stretching exercises, nonsteroidal anti-inflammatory medications, local steroid injections, and extracorporeal shock wave therapy, is the cornerstone of treatment [3,9-12]. Patients who do not respond adequately to nonoperative treatment may require calcaneal osteotomy with or without Achilles tendon debridement, excision of the retrocalcaneal bursa, or endoscopic decompression, which involves debridement of the inflamed retrocalcaneal bursa with/without resection of the postero-superior aspect of the calcaneus [13,14]. When compared to open techniques, minimally invasive procedures, such as endoscopic techniques, provide a superior image of the retrocalcaneal space, have a shorter postoperative recovery period, less postoperative pain, and a lower complication rate [15-19].

This study was conducted to evaluate the clinical efficacy of endoscopic decompression and debridement in patients with retrocalcaneal bursitis who had not responded to conservative treatment. Our primary objective was to estimate the improvement in American Orthopaedic Foot and Ankle Society (AOFAS) score after surgery, and our secondary objectives were to estimate the average surgical duration and the incidence of post-operative complications.

Material and methods

This was an intervention study conducted at a single tertiary centre. Included in the study were all patients who were diagnosed with retrocalcaneal bursitis and who had failed a minimum 6-month trial of conservative treatment. Retrocalcaneal bursitis was suspected based on the senior author's clinical evaluation, which revealed pain and swelling in the retrocalcaneal region for over six weeks, along with difficulty walking and pain in ankle plantar flexion against resistance. Patients who met the aforementioned criteria underwent a clinical examination, a roentgenographic examination of the ankle (axial and lateral views), and an MRI of the heel. On MRI, patients with retrocalcaneal bursitis were included in the study. Excluded from the study were patients with a history of retrocalcaneal steroid injection, hind foot surgery, anatomical foot deformities such as cavus or valgus foot, gout, spondyloarthropathies including rheumatoid arthritis, and infective retrocalcaneal bursae. Additional patients with calcific Tendo Achilles tendinitis detected on lateral ankle X-rays were excluded from the study. Patients who finally met these criteria were enrolled in the study after obtaining their informed consent. 36 patients (36 heels) underwent endoscopic decompression. There were 22 women and 14 men present. The range of ages was 19-53 years, with a mean of 36.19 years. 20 procedures were performed on the right side and 16 procedures were performed on the left. On the patient proforma, the demographic information, medical history, and examination findings were recorded. The presence/absence of Achilles tendon calcification, neurovascular status, American Orthopaedic Foot and Ankle Society (AOFAS) score, and amount of bone to be resected were evaluated preoperatively using the criteria outlined by Kondaredi et al. [4] (Figure 1). To assess bony projection on the posterior aspect of the calcaneum, two parallel pitch lines were drawn. The baseline is formed by the lower line, which extends from the anterior tubercle to the medial posterior tubercle. The upper line is drawn parallel to the line above, beginning at the talar articular surface and ending at the posterior tuberosity. The prominence of the bony projection above the upper line necessitates surgical excision.

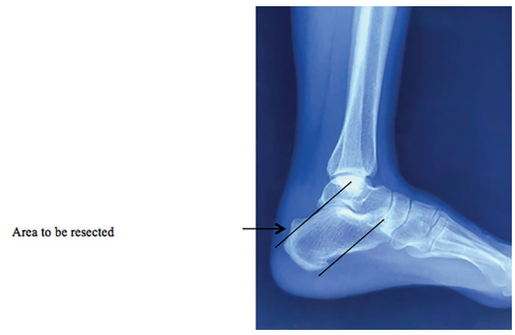

Figure 1 - Radiograph (lateral view) depicting area of calcaneum that requires resection

Operative technique

The patient was placed in a prone position with one foot hanging over the table's edge during the procedure. Utilizing a pneumatic tourniquet with a pressure setting of 270 mm of mercury, the bleeding was controlled. Antibiotics of the third generation were administered 15 minutes prior to surgery as a precaution. A stab incision was made just above the line drawn from the tip of the lateral malleolus to the Achilles tendon insertion and in front of the Achilles tendon to create the lateral portal. A trocar was inserted gently into the retrocalcaneal space. The 4mm 30° arthroscope was developed. For the insertion of an arthroscopic shaver, a spinal needle was inserted on the medial side, directly opposite the lateral side, under direct visualisation. A medial portal was created in front of the Achilles tendon's medial edge. A hemostat was introduced to the arthroscope, and a space was created for the introduction of a shaver. From the medial side, a 4mm arthroscopic shaver was introduced. The retrocalcaneal bursa was observed and resected using a razor (Figures 2 (a), 2 (b).

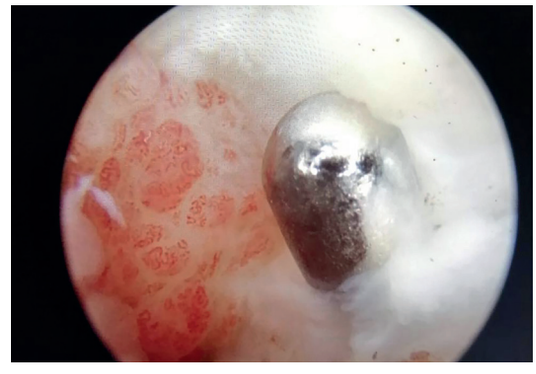

Figure 2 (a) - Shaver resecting inflamed bursa

Figure 2 (b) - Endoscope view of retrocalcaneal space

Figure 3 (a) - Preoperative radiograph (lateral view)

Figure 3 (b) - Post Operative radiograph (lateral view) at end of 6th month

The opposite side of the calcaneum from the Achilles tendon was abraded. To prevent tendon injury, the hooded portion of the instruments was kept towards the tendon. For the resection of the posterosuperior aspect of the calcaneum, a burr was introduced. The bone was resected from the posterior to the anterior. The bone was resected up to the Achilles tendon attachment. The margins were smoothed with a curette or an arthroscopic bone file. Under arthroscopic observation, hyperplanterflexion and dorsiflexion of the foot were performed to rule out signs of impingement. The fragments were irrigated with copious quantities of normal saline and then vacuumed. The portal sites were injected with a local anaesthetic. There were no drains used. In relaxed equinus, the portal sites were sutured with 2-0 mattress sutures and a removable below-knee slab was given. Postoperatively, the foot was splinted in relaxed equines, and the patient was advised not to bear weight for ten to fourteen days. The sutures were removed after fourteen days. The splint was then removed and replaced with a walking boot (with a 1-inch heel) for the following two weeks. After four weeks, normal walking was resumed with normal shoes.

Postoperative protocol: All patients followed a similar postoperative protocol. In the second to third week, ankle range of motion and Achilles tendon stretching exercises were initiated. The patient was observed at 1 week, 2 weeks, 4 weeks, 3 months, and 6 months. At each follow-up visit, ankle range of motion, AOFAS Score, and any recurrence or persistence of pain or deformity were recorded. Each visit involved lateral X-rays (Figures 3 (a), 3 (b). The scoring was done by uninvolved surgeon. Each of the 36 patients was monitored. There was no subsequent loss.

Analytical statistics

Using the Kolmogorov-Smirnov test, the normality of the data was examined. Using the Wilcoxon signed rank test, quantitative variables (preoperative and postoperative AOFAS scores) were compared. The Kruskal Wallis test was used to compare the association between outcome and age group, and the Mann Whitney test was used to compare the association between outcome and side. A p value of less than 0.05 was deemed statistically significant. The data were entered into an MS EXCEL spreadsheet, and SPSS version 21.0 was used for analysis.

Results

It was a prospective interventional cohort study conducted on a total of 36 adult patients (18-70 years of age) with clinical and radiological findings suggestive of retrocalcaneal bursitis, duration of failed conservative treatment prior to surgery > 6 months, and refractoriness to other forms of non-operative treatment such as steroid injections regardless of duration. There were no patients lost to follow-up. The mean duration of follow-up was 6 months [6 months to 2 years]. The mean pre-operative AOFAS score was 56.42±6.8 with a range of 44 to 70. It increased to 65.56±5.32 at the first week, 73.5±3.26 at the second week, 85.25±3.81 at the fourth week, 93.69± 5.09 at the third month, and 95.67±4.85 at the end of the sixth month. The difference between preoperative and postoperative AOFAS scores at 1 week, 2 weeks, 4 weeks, 3 months, and 6 months was statistically significant (p=0.0001). Ten patients with retrocalcaneal bursitis and non-insertional Achilles tendinosis had mean pre-operative AOFAS scores of 51.4±5.98, which improved to 93.1±8.8 at the end of 6 months. In contrast, the mean pre-operative AOFAS Scores of 26 patients with retrocalcaneal bursitis alone increased from 53.15±4.13 at the end of the first week to 96.65±1.05 at the end of the sixth month. Both groups of patients showed significant improvement. The preoperative scores of the two groups did not differ statistically [p=.42], but patients with retrocalcaneal bursitis alone reported better outcomes than those with non-insertional Achilles tendinosis [p=.001]. The mean improvement in AOFAS score at 6 months was 47.89 when preoperative AOFAS scores were <50, 43.75 when preoperative AOFAS scores were between 51-55, 35.11 when preoperative AOFAS scores were between 56-60, 33.83 when preoperative AOFAS scores were between 61-65, and 28.25 when preoperative AOFAS scores were >65. Lesser the preoperative AOFAS score, which is indicative of disease severity, the greater the magnitude of postoperative improvement after arthroscopic decompression. Consequently, there is a positive correlation between disease severity (as measured by low AOFAS scores) and the magnitude of AOFAS score improvement in the postoperative period (Correlation coefficient = -0.946; p value 0.0001). However, no correlation was found between age and disease outcome (p=0.923) or between side of pathology and disease outcome (p=0.867). 1

(2.78%) of 36 subjects experienced persistent pain even after surgery, and the patient complained of pain throughout the entire 6-month follow-up period. Other treatment methods were attempted on the patient, but none were successful. The patient was advised to undergo an MRI and was counselled regarding the need for an open resection, but the patient refused. Four out of thirty-six patients (11.11%) complained of postoperative swelling around the incision site that persisted until suture removal at 14 days and was alleviated by limb elevation, active ankle range of motion exercises, and cold compressions. There were no intraoperative complications, altered sensations at the surgical site, surgical site infections, Achilles tendon ruptures, or neurovascular deficits.

Discussion

The study demonstrates that endoscopic decompression and debridement of the retrocalcaneal space is an effective procedure for the minimally complication-prone management of patients with retrocalcaneal bursitis who have failed adequate conservative treatment. Cases with less severe disease and no insertional tendinitis fared better than those with severe disease or insertional tendinitis, according to additional research.

Retrocalcaneal bursitis is a common condition that causes morbidity in a substantial proportion of patients.

The first line of treatment [4,12] includes the use of analgesics, hot saline fomentation, gastrocnemius and soleus stretching exercises, and the avoidance of tight shoes. If initial conservative treatment fails in certain conditions, steroid injections have also been used, but they cause Achilles tendon rupture [10,20]. In our study, no steroid injections were administered. Leitze et al. [4] reported a 10% failure rate for conservative therapy. In contrast, Sammarco et al. [21] reported a 65% failure rate with conservative treatment. Retrocalcaneal bursitis and Haglund deformity patients who do not respond adequately to non-operative treatment have numerous open surgical options, including calcaneal osteotomy with or without Achilles tendon debridement and retrocalcaneal bursectomy [13,14]. Nonetheless, these extensive open surgical techniques were linked to complications such as skin breakdown, Achilles tendon avulsion, mutilating scars, altered sensation, and joint stiffness [4].

The problems with open surgery led to the rise in popularity of minimally invasive surgeries [15]. Ortmann F.W. et al. performed endoscopic debridement and discovered that the average postoperative AOFAS score significantly increased (97 from preoperative score of 62). There were no intraoperative complications noted. 19 days after surgery, 1 patient developed an Achilles tendon rupture requiring primary repair. 1 patient complained of persistent pain, necessitating reoperation with open decompression and debridement [3]. Similarly, Van Dijk et al. performed 21 Endoscopic Calcaneoplasty procedures on 20 patients who had failed to respond to conservative treatment for at least six months. The mean duration of follow-up was 3.9 years. According to the Ogilvie-Harris score, the study yielded 15 excellent results, 4 good results, and 1 fair result. There were no surgical complications reported [16]. Jerosch J. performed endoscopic calcaneoplasty and discovered excellent results in 84 patients, good results in 71 patients, and fair and poor results in 5 and 4 patients, according to the Oglivie-Harris score. The study found that more than 90% of patients had excellent or good results without any of the complications associated with open procedures, such as wound dehiscence, lesions in the Achilles tendon, scar irritation, transformation to keloid, pain persistence, and hypesthesia of the skin overlying the scar [22].

Similar to these findings in the literature, we discovered that endoscopic decompression is an effective treatment for retrocalcaneal bursitis in patients.

In a study of 33 heels treated with endoscopic decompression, Leitze et al. found that 9 had excellent results, 5 had good results, 3 had fair results, and 3 had poor results [4]. The average AOFAS score for patients treated with an endoscopic approach was 61.8 pre-op and 87.5 post-op (p=0.001), whereas the average AOFAS score for patients treated with open surgery was 58.1 pre-op and 79.3 post-op (p=0.006). There were no intraoperative complications reported. In the endoscopic group, one patient had a wound infection, one reported sural neuropathy, one reported heel numbness, and one reported symptoms similar to sympathetic dystrophy. Similar to our observation, their study discovered that the greater the severity of disease preoperatively, the greater the magnitude of improvement postoperatively, indicating a correlation between the preoperative score and the magnitude of improvement (0.048). Nonetheless, no correlation was found between age and outcome or postoperative resection angle and outcome, similar to the present study's findings.

Operating time reveals a steep learning curve for endoscopic procedures. The average operating time decreased to 40 minutes from an initial 75 minutes. Patients with retrocalcaneal bursitis alone reported better outcomes than those with non-insertional Achilles tendinosis, as determined by Kondreddi et al. [3].

Leitze et al. discovered a correlation between disease severity (as measured by low AOFAS scores) and the magnitude of improvement in AOFAS score in the postoperative period (Correlation coefficient, -0.946; p value 0.0001) [4]. Similar to the results reported by Leitze et al., we also found no correlation between age and disease outcome (p=0.923) or between the side of pathology and disease outcome (p=0.867).

This study has several limitations, including the absence of a control group for comparison, a relatively short follow-up period of only 6 months, the inability to measure the effect of different angles of calcaneum resection on outcome, the inability to compare calcific and non-calcific degeneration, and the small sample size.

Conclusion

In patients with retrocalcaneal bursitis, arthroscopic decompression is a safe, effective, and simple procedure. Within the first three months, the majority of study participants experienced pain relief and a significant improvement in function. The procedure offers benefits such as minimal blood loss, direct visualisation of the structures, accelerated functional recovery, and a low complication rate. It can be concluded that patients without tendon degeneration benefit more than those with tendon degeneration. Second, a positive correlation has been identified between disease severity (as measured by a low AOFAS score) and the magnitude of improvement at the end of the follow-up period.

Disclosures: There is no conflict of interest for all authors.

Acknowledgements: Authors acknowledge the contribution of Aryaman Jaiman, MBBS Student, Agartala Government Medical College, Agartala, Tripura, India, 799006 for his assistance with statistical analysis, grammar editing, and plagiarism detection.

Funding: None.

References

1. Sutro CJ. The os calcis, the tendo-Achilles and the local bursae. *Bull Hasp ft Dis.* 1966; 27:76-89.
2. Canoso JJ, Liu N, Traill MR, Runge VM. Physiology of the retrocalcaneal bursa. *Ann Rheum Dis.* 1988; 47(11):910-2. https://doi.org/10.1136/ard.47.11.910
3. Kondreddi V, Gopal RK, Yalamanchili RK. Outcome of endoscopic decompression of retrocalcaneal bursitis. *Indian J Orthop*. 2012; 46(6):659-63. https://doi.org/10.4103/0019-5413.104201
4. Leitze Z, Sella EJ, Aversa JM. Endoscopic decompression of the Retrocalcaneal Space. *J Bone Joint Surg Am.* 2003; 85(8):1488-96. https://doi.org/10.2106/00004623-200308000-00009
5. Young JL, Olsen NK, Press JM. Musculoskeletal disorders of the lower limbs. In: Braddom RL, ed. Physical Medicine and Rehabilitation. Philadelphia, Pa: WB Saunders Co; 1996:783-812.
6. McGee DJ. Lower leg, ankle, and foot. Orthopedic Physical Assessment. 2nd ed. Philadelphia, Pa: WB Saunders Co; 1992:448-515.
7. Chimenti RL, Cychosz CC, Hall MM, Phisitkul P. Current Concepts Review Update: Insertional Achilles Tendinopathy. *Foot Ankle Int.* 2017; 38(10):1160-9. https://doi.org/10.1177/1071100717723127
8. Aldridge T. Diagnosing heel pain in adults. Am Fam Physician.2004; 70:332-8.
9. Lowdon A, Bader DL, Mowat AG. The effect of heel pads on the treatment of Achilles tendinitis: A double blind trial. *Am J Sports Med.* 1984; 12(6):431-5. https://doi.org/10.1177/036354658401200605
10. Fredberg U. Local corticosteroid injection in sport: review of literature and guidelines for treatment. *Scand J Med Sci Sports. 1*997; 7(3):131-9. https://doi.org/10.1111/j.1600-0838.1997.tb00129.x
11. Furia JP. High-energy extracorporeal shock wave therapy as a treatment for insertional Achilles tendinopathy. *Am J Sports Med. 2006;* 34(5):733-40. https://doi.org/10.1177/0363546505281810
12. Clancy WG. Runners' injuries. Part two: Evaluation and treatment of specific injuries. *Am J Sports Med.* 1980; 8:287-9. https://doi.org/10.1177/036354658000800415
13. Angermann P. Chronic retrocalcaneal bursitis treated by resection of the calcaneus. *Foot Ankle.*1990; 10(5):285-7. https://doi.org/10.1177/107110079001000508
14. Brunner J, Anderson J, O'Malley M, Bohne W, Deland J, Kennedy J. Physician and patient based outcomes following surgical resection of Haglund's deformity. *Acta Orthop Belg.* 2005; 71(6):718-23.
15. Weil LS. Minimal invasive surgery of the foot and ankle. *J Foot Ankle Surg*. 2001; 40:61. https://doi.org/10.1016/S1067-2516(01)80046-6
16. van Dijk CN, van Dyk GE, Scholten PE, Kort NP. Endoscopic calcaneoplasty. *Am J Sports Med*. 2001; 29(2):185-9. https://doi.org/10.1177/03635465010290021101
17. van Dijk CN, Scholten PE, Krips R. A 2-portal endoscopic approach for diagnosis and treatment of posterior ankle pathology. *Arthroscopy*. 2000; 16(8):871-6. https://doi.org/10.1053/jars.2000.19430
18. Van Dijk CN, Sholten PE, Kort N. Tendoscopy (tendon sheath endoscopy) for overuse tendon injuries. *Oper Tech Sports Med.* 1997; 5(3):170-8. https://doi.org/10.1016/S1060-1872(97)80039-1
19. Kitaoka HB, Alexander IJ, Adelaar RS, Nunley JA, Myerson MS, Sanders M. Clinical rating systems for the ankle-hindfoot, midfoot, hallux, and lesser toes. *Foot Ankle Int.* 1994; 15(7):349-5. https://doi.org/10.1177/107110079401500701
20. Kennedy JC, Willis RB. The effects of local steroid injections on tendons: a biomechanical and microscopic correlative study. *Am J Sports Med*. 1976; 4(1):11-21. https://doi.org/10.1177/036354657600400103
21. Sammarco GJ, Taylor AL. Operative management of Haglund's deformity in the nonathlete: a retrospective study. *Foot Ankle Int.*1998; 19(11):724-9. https://doi.org/10.1177/107110079801901102
22. Jerosch J. Endoscopic Calcaneoplasty. *Foot Ankle Clin.* 2015; 20(1):149-165. https://doi.org/10.1016/j.fcl.2014.10.004