JOURNAL OF CLINICAL MEDICINE OF KAZAKHSTAN (E-ISSN 2313-1519)
Original Article DOI: https://doi.org/10.23950/jcmk/12285

Morphology of echinococcal liver lesions during treatment with high-intensity focused ultrasound

Galina Fedotovskikh[1], Galiya Shaymardanova[1], Nurlan Zhampeissov[2]

[1]*Pathomorphology Department, National Scientific Medical Center, Nur-Sultan, Kazakhstan*
[2]*HIFU Therapy and Ultrasound Imaging Department, National Scientific Medical Center, Nur-Sultan, Kazakhstan*

Received: 2022-06-06.
Accepted: 2022-06-23

J Clin Med Kaz 2022; 19(4):28-31

Corresponding author:
Galina Fedotovskikh.
E-mail: gvf_fedotovskikh@mail.ru;
ORCID: 0000-0003-2416-7385

Abstract

Aim: The purpose of morphological studies was to study pathogenetic mechanisms of the therapeutic effect of HIFU ablation on hepatic echinococcosis.

Material and methods: Ablation of echinococcal cysts and alveococcal liver lesions no larger than 5 cm in size with high-intensity focused ultrasound was performed on JC Focused Ultrasound Therapeutic System (China). Biopsy material of hepatic echinococcal masses in 37 patients after HIFU-ablation were taken for morphological light-optical and electron microscopic studies.

Results: Protoscolexes lost their superficial syncytial layer, the parenchyma looked vacuolized, the disembodied heads with suckers and hooks were fragmented and separated from the body. Small vacuolization of hyaloplasm, homogenization of membranes and mitochondrial matrix, blurring of organelle contours in parenchymatous protoscolex cells were observed. Laminar shells of brood capsules and larvocysts of echinococcus were homogenized and ruptured, germinative cells were sloughed off. The laminar and germinal sheaths of the alveolar vesicles were irregularly thickened, unfolded, ruptured, and surrounded by necrotized liver cells and structureless masses. Destructively altered stem cells and calcareous calcium corpuscles of the laryngeal membrane were observed electron microscopically.

Conclusion: Morphological data revealed destructive effect of HIFU ablation on mature and germinative forms of hydatid and alveolar echinococcus of the liver, as well as the safety of the selected optimal HIFU power on the surrounding hepatic tissue, which explains the absence of recurrence and confirms high effectiveness of HIFU ablation as a minimally invasive method of treatment of echinococcal growths of certain acceptable sizes.

Key words: hepatic echinococcosis, high-intensity focused ultrasound, light-optical and electron microscopic morphology

Dedicated to the blessed memory of Professor Imankulov Suindyk Bopezhanovich.

Introduction

High-intensity focused ultrasound (HIFU) is a new and successful noninvasive method of treating tumors of various localizations [1, 2]. The theoretical foundations of HIFU ablation, established back in the 1940s at the University of Illinois, were implemented as a result of the creation of high-tech equipment model JC Focused Ultrasound Therapeutic System (Chongqing HAIFU Technology Co., China). Without damaging the skin or healthy organs, the method creates a high- energy concentration of radiation in the focus of the tumor, resulting in a second death of tumor cells. Total safety of the method, efficiency of use in primary and metastatic tumors of many organs, combination with any type of systemic exposure (chemo-, radiation and immunotherapy) led to the use of NIFU for ineffective surgical and palliative treatment of tumors. In 2010, Prof. S.B. Imankulov for the first time proposed the use of NIFU as a mini-invasive method of treatment of hydatidosis and alveolar echinococcosis of the liver in conditions of continuing severe emidemiological situation and unsolved many issues of the course, diagnosis and treatment of hepatic echinococcosis [3-5]. The developed indications and contraindications for HIFU use in hepatic echinococcal lesions, permissible sizes of parasitic masses, selection of optimal HIFU power, analysis of immediate and long-term results, comparative assessment of traditional surgical intervention and HIFU ablation were the basis for positive results and effective treatment of alveolar and hydatid liver echinococcosis by HIFU ablation [6-8].

The purpose of morphological studies was to study pathogenetic mechanisms of the therapeutic effect of HIFU ablation on hepatic echinococcosis. Presented at the international level in the form of reports [9-12], they are presented in full in the present work and dedicated to the blessed memory of Suindyk Bupezhanovich Imankulov.

Material and methods

Ablation of echinococcal cysts no larger than 5 cm in size with high-intensity focused ultrasound was performed on JC Focused Ultrasound Therapeutic System (Chongqing HIFU Technology Company, China) with a 15 cm diameter treatment lens, 0.9 MHz radiation frequency with the focused ultrasound traveling vertically in 5 mm slices. Power of radiation intensity averaged over time was 180 - 250 W. Centrifugate and biopsy material of hepatic echinococcal masses in 37 patients before, during the nearest (3-4 days) and long term (6 months) after HIFU-ablation were taken for morphological light-optical and electron microscopic studies. Transcutaneous puncture was performed under the control of ultrasound imaging. Safe taking of lifetime biopsy material of echinococcal cysts contents after Hi-Fu ablation was ensured by qualified performance and experience, special equipment and careful observance of the technique. The effectiveness of ablation was determined by computerized, magnetic resonance imaging and ultrasound examination. The cytological smears were stained by Papanicolaou. Histological and electron microscopic material was obtained according to conventional methods. Histological sections were stained with hematoxylin and eosin. Semi-thin sections (high-resolution light-optical microscopy) were stained with methylene blue, azure-2, and basic fuchsin [13]. Ultrathin sections were contrasted with uranyl acetate, Reynolds lead citrate, and studied in a Libra-120 electron microscope (Carl Zeiss).

Results

On cytological and light-optical examination of the contents of hydatid echinococcal cysts in the immediate aftermath of thermal and cavitational HIFU ablation the sedimentary material included, in addition to echinococcal structures, destroyed inflammatory cells, small vacuolar, granular material and calcareous crystals (Figure 1 A). Electron microscopically, the contents and superficial layered membranes of even the smallest ultrastructures ranging in size from 200 to 800 nm were necrotic (Figure 1 B). In the light-optical study of protoscolexes on cytomasks and semi-thin sections, there was a sharp decrease in their size due to gelation (Figure 1 C). Protoscolexes lost their superficial syncytial layer, the parenchyma looked vacuolized, the disembodied heads with suckers and hooks were fragmented and separated from the body. At the ultrastructural level, small vacuolization of hyaloplasm, homogenization of membranes and mitochondrial matrix, blurring of organelle contours in parenchymatous protoscolex cells were observed (Figure 1 D).

Laminar shells of brood capsules and larvocysts of echinococcus were homogenized and ruptured at the light-optical level, germinative cells were sloughed off (Figure 2 A). At high magnification, sharp cleavage of chitin sheath plates was clearly visible (Figure 2 B).

Electron microscopically, the surface of the fibrous layers of the chitin sheath plates was necrotic and had an osmiophilic appearance (Figure 2 C). The less dense inner granular layers of the plates contained electron-transparent vacuolized granular aggregates. The hyaloplasm of the glycogen-containing cells of the germinal membrane was ruptured, and the organelles were "fused" (Figure 2 D).

The condition of the echinococcal cyst wall itself was assessed by pathomorphological histological examination of rare surgical material that underwent HIFU ablation. The germinal

Figure 1 - Contents of echinococcal cyst 3 days after HIFU ablation. A - sedimentary material of echinococcal cyst contents. Semi-thin slice x 1000. B - necrosis of fine ultrastructure. Electronogram x 34,000. C - helicization and vacuolization of cytoplasm, detachment of protoscolex heads. Cytological smear preparation. Papanicolaou staining x 1 000. D - vacuolization of hyaloplasm and destruction of organelles in protoscolex cells. Electronogram x 24 000.

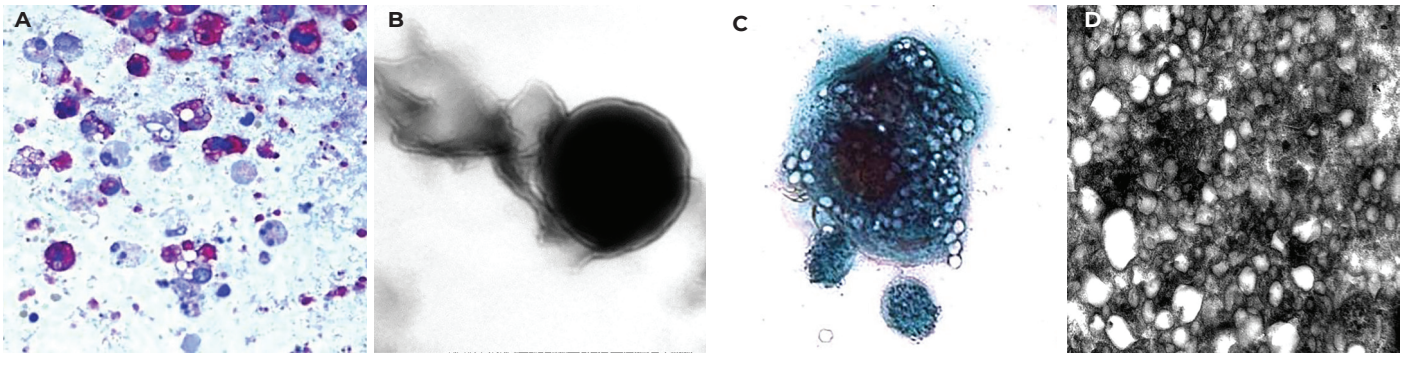

Figure 2 - Contents of echinococcal cyst 3 days after HIFU ablation. A - homogenization, laminar sheath rupture, desquamation of germinal sheath of brood capsules and larvocysts of echinococcus. Semi-thin slice x 500. B - delamination of laminar shell plates. Semi-thin slice x. 1000. C - necrosis of surface of fibrous layers, vacuolization of granular aggregates of internal layer of laminar shell plates. Electronogram x 30,000. D -destruction of glycogen-containing cell of laryngeal lamina membrane. Electronogram x 24 000.

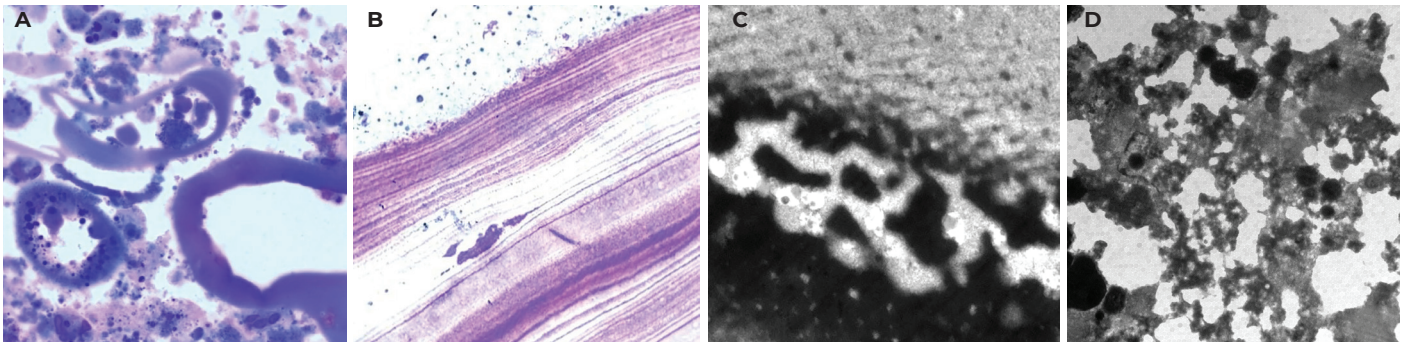

layer of the cyst and the protoskeletons and brood capsules attached to the cambial zone were destroyed (Figure 3A). The chitin sheath layers were delaminated, fragmented, and necrotized (Figure 3 B). The fibrous sheath of hydatid echinococcus, where protoscolexes might normally be located, was characterized by a broad zone of the inner necrotic layer, although in small cysts the necrotic layer might have been absent. The hyaline layer showed granular disintegration of collagen fibrils (Figure 3 C). The outer layer of loose connective tissue with inflammatory cells and vessels was loosened. Adjacent to the fibrous capsule, the liver tissue was characterized by hepatocyte dystrophy, hepatic trabeculae rearrangement and periportal connective tissue overgrowth common in echinococcosis (Figure 3 D).

Figure 3 - Echinococcal cyst wall 3 days after HIFU ablation. A - thinning, destruction of germinal layer of the wall and brood capsule of echinococcal cyst. Histological section x 200. B - delamination and necrosis of chitin sheath plates of echinococcal cyst. Histological section x 400. C - granular disintegration of collagenous fibrils of hyaline layer, loosening of outer layer of loose connective tissue. Histological section x 200. D - dystrophy of hepatocytes, rearrangement of hepatic trabeculae, overgrowth of periportal connective tissue of hepatic tissue. Histological section x 200.

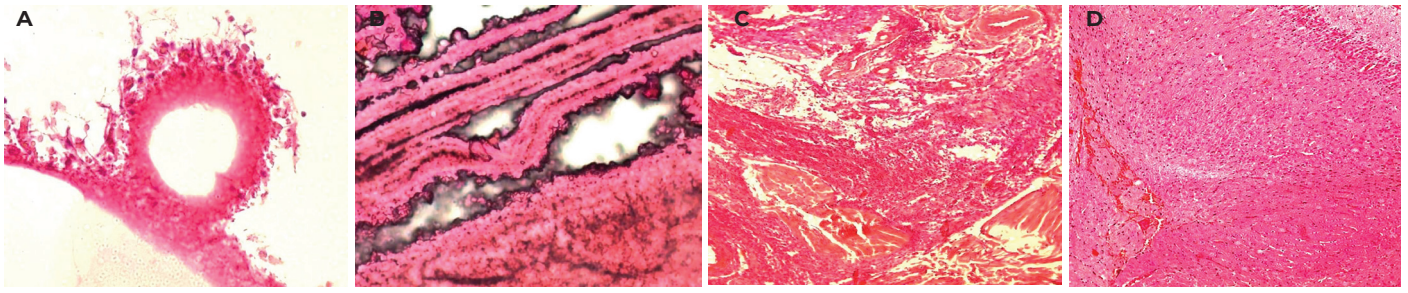

Figure 4 - Alveococcus of the liver 3 days after HIFU ablation. A - Destruction of protoscolex and laminae of alveococcal vesicles. Histological section x 400. B - Destruction of alveococcal larvocysts. Semi-thin slice x 1000. C - fragments of the destroyed calcium-containing cell. Electronogram x 34,000. D - numerous feather-like microcapsules. Semi-thin slice x 1000. E - microcapsules attached to and detached from the chitin sheath of alveococcus. Semi-thin slice x 1000. F - Destruction of the cell membrane of the microcapsule. Electronogram x 40000.

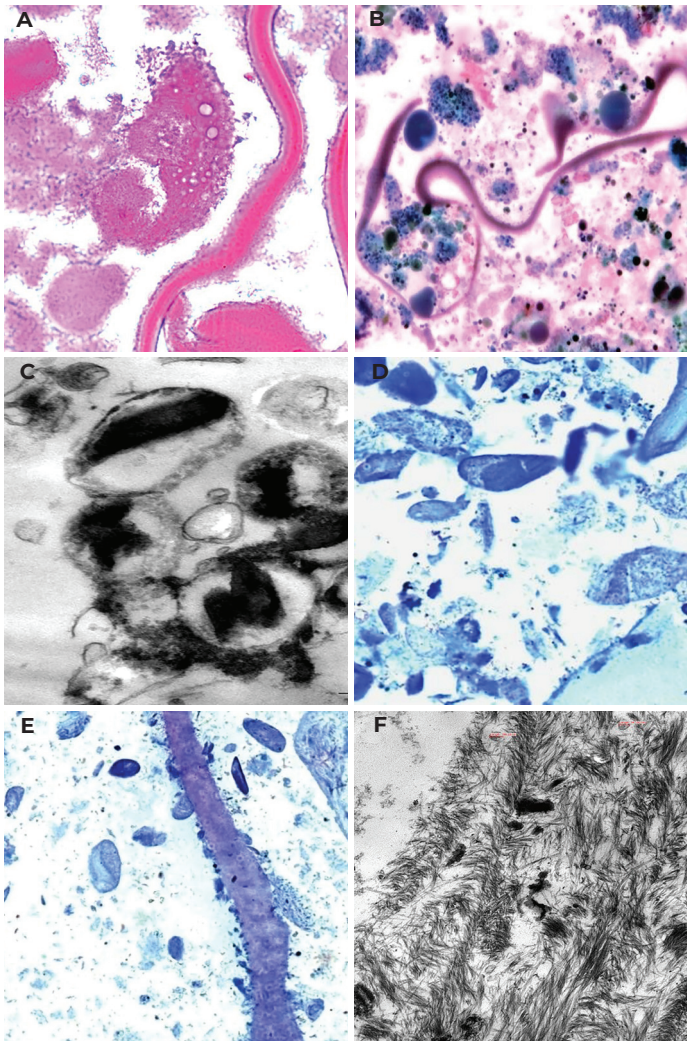

After HIFU-ablation of alveococcal liver lesions, destructively altered blurred contours of alveolar vesicles were seen cytologically. The histological material showed destruction of the body of germinal scolexes and laminae of alveococcus (Figure 4 A). On semi-thin sections, the laminar and germinal sheaths of the vesicles were irregularly thickened, unfolded, ruptured, and surrounded by necrotized liver cells and structureless masses (Figure 4 B). Destructively altered stem cells (amebocytes) and calcareous calcium corpuscles of the laryngeal membrane were observed electron microscopically (Figure 4 C). Of certain interest were peculiar microcapsules of irregular "feather-like" shape of different sizes (Figure 4 D). Close connection of microcapsules with ruptured chitinous shells of larvocysts was noted (Figure 4 E). Electron microscopically, the microcapsules were about 18 thousand nanometers in size and consisted of fibrillar structures similar to the chitin sheath structure of larvocysts. The ultrastructure of the outer membrane of the microcapsules was destroyed (Figure 4 F).

At 6 months after HI-FU exposure, fields of fibrinoid necrosis with altered alveolar larvocysts were determined histologically in the operatively removed material. Chitin sheaths of larvocysts were homogenized, unstructured. Cellular elements of the germinal layer and the contents of larvocysts were necrotic. Necrotically altered areas of the liver and larvocysts of alveococcus were surrounded by fibrous and granulation tissue overgrowth with pronounced plasmacytic and leukocytic infiltration.

Discussion

Thus, high - intensive focused ultrasound ablation caused destruction of both germinal forms of hydatidosis echinococcus protoscolex and all elements of the germinal shell of brood capsules and larvocysts, which are the carriers of all life functions of the parasite [14]. Fine vacuolization of hyaloplasm, homogenization of mitochondrial membranes and matrix, blurring of organelle contours testified to the termination of all redox processes in parenchymatous, including germinative cells of protoscolex stem from which acephalocysts develop, more stable and dangerous in terms of invasion [15]. We did not encounter acephalocysts themselves in the echinococcal cyst contents, although small ultrastructural fragments of destroyed

cells (from 200 to 800 nm) could belong to the destroyed parts of acephalocysts, constituting one to two thousandth of their size (100-200 microns). Our assumption is confirmed by the absence of relapses in this method of echinococcus treatment.

The echinococcal cyst wall was characterized by dissection and necrosis of all chitinous shell layers, where transcutaneous channels with protoscolexes and even small parasitic cysts located in them are formed during active parasite fertilization, contributing to exogenous echinococcal dissemination. It is also extremely important that HIFU ablation did not lead to severe destructive changes in the liver, preserving the functions of the organ.

After HIFU ablation of alveolar echinococcus electron microscopically revealed destruction of stem cells (amebocytes) and numerous calcareous calcium corpuscles of the laryngeal shell, presumably being temporarily inactivated by mineralization stem cells, playing an important role in alveococcal metastasis [16]. An interesting finding was the discovery of peculiar microcapsules closely associated with the ruptured chitin sheaths of larvocysts. The fibrillar structure of the microcapsules was identical to that of the chitin sheath of larvocysts. Assuming the relation of these structures to the poorly studied genesis of alveococcal brood capsules, there is no doubt that HIFU ablation, causing destruction of the outer membrane of microcapsules, destroyed even the most initial forms of this parasite development. In the distant terms after HIFU exposure the pathologically changed alveolar larvocysts were necrotized and littered with fields of fibrous and granulation tissue, which indicated a complete blockade of alveolar echinococcal development.

Conclusion

Morphological data revealed destructive effect of HIFU ablation on mature and germinative forms of hydatid and alveolar echinococcus of the liver, as well as the safety of the selected optimal HIFU power on the surrounding hepatic tissue, which explains the absence of recurrence and confirms high effectiveness of HIFU ablation as a minimally invasive method of treatment of echinococcal growths of certain acceptable sizes.

Disclosures: There is no conflict of interest for all authors.

Acknowledgements: None.

Funding: None.

References

1. Li CX, Xu GL, Jiang ZY, Li JJ, Luo GY, Shan HB, Zhang R, Li Y. Analysis of clinical effect of high-intensity focused ultrasound on liver cancer. *World J Gastroenterol*. 2004;10(15):2201-4. https://doi.org/10.3748/wjg.v10.i15.2201
2. Wu F, Wang ZB, Chen WZ, Zou JZ, Bai J, Zhu H, Li KQ, Jin CB, Xie FL, Su HB. Advanced hepatocellular carcinoma: treatment with high-intensity focused ultrasound ablation combined with transcatheter arterial embolization. *Radiology*. 2005; 235(2):659-67. https://doi.org/10.1148/radiol.2352030916
3. Vetshev P.S., Musaev G.Kh. Hydatidosis: Point of View. Annals of surgical hepatology. 2005; 4: 7-12. (In Russ.).
4. Vishnevsky V.A., Ikramov R.Z., Kakharov M.A., Yefanov M.G. Radical treatment of liver echinococcosis. State of art [In Russian]. *Bulletin of Siberian Medicine.* 2007;6(3):22-26. https://doi.org/10.20538/1682-0363-2007-3-22-26
5. Ordabekov S.O., Ordabekov E.S., Temirova Z.I. On the modern approach to treatment of hepatic echinococcosis [In Russian]. *Bulletin of surgery in Kazakhstan. Almaty.* 2005; (2): 55-57.
6. Imankulov SB, Fedotovskikh GV, Zhampeissov NK, Yerlan M, Shaimardanova GM, Knaub LV. Treatment of liver alveococcosis with high-intensity focused ultrasound. *Ultrason Sonochem*. 2015; 27:707-711. https://doi.org/10.1016/j.ultsonch.2015.05.022
7. Imankulov SB, Fedotovskikh GV, Shaimardanova GM, Yerlan M, Zhampeisov NK. Feasibility study of high intensity focused ultrasound (HIFU) for the treatment of hydatid cysts of the liver. *Ultrason Sonochem.* 2015; 27:712-716. https://doi.org/10.1016/j.ultsonch.2015.05.025
8. Zhampeissov N, Manap E, Rustemova K, Fedotovskikh G, Tuganbekov T, Imankulov S, Gaipov A. High-intensity focused ultrasound ablation: a non- surgical approach to treat advanced and complicated liver alveococcosis. *J Med Ultrason* (2001). 2019;46(2):251-255. https://doi.org/10.1007/s10396-018-0914-x
9. G. Fedotovskikh. Morphological estimation of efficacy of Hi-Fu ablation of the liver hidatid and alveolarisexinococcus. / The 3 Yangtze International Summit of Minimally-invasive and Noninvasive Medicine of ISMINIM, China, July 13-16, 2017.
10. G.V. Fedotovskikh. Morphological evaluation of the effectiveness of HIFU therapy in the treatment of echinococcal lesions of the liver. International scientific-practical conference "Possibilities of HIFU therapy in treatment of tumor formations and parasitic cysts of parenchymatous organs of the abdominal cavity and kidneys" October 24, 2017.Bishkek. Kyrgyzstan. [In Russian].
11. Fedotovskikh G.V., Imankulov S.B., Zhampeisov N.K. "Efficiency of high-intensity focused ultrasound (HIFU) in treatment of liver echinococcosis according to morphological study". VII Annual International Scientific and Practical Conference "Topical Questions of Medicine" and "Satellite Forum on Public Health and Health Policy". May 2-3, 2018 Baku, Azerbaijan. [In Russian].
12. G.V. Fedotovskikh. Morphological evaluation of the effectiveness of high-intensity focused ultrasound in the treatment of hydatidosis and alveolar echinococcosis of the liver. SCO Hospitals Cooperation Alliance Forum, Cholpon-Ata, Kyrgyzstan. September 13-14, 2019. [In Russian].
13. Humphrey CD, Pittman FE. A simple methylene blue-azure II-basic fuchsin stain for epoxy-embedded tissue sections. *Stain Technol.* 1974;49(1):9-14. https://doi.org/10.3109/10520297409116929
14. Nazirov F.G., Ismailov D.A., Leonov V.F., Baybekov I.M. Echinococcosis [In Russian]. Tashkent. 1999 -207.
15. Kovalenko F.P. et al. Experimental imaginal multicompartment echinococcosis of golden; hamsters [In Russian]. *Med. parasitol. and parasitic diseases.* 1990; 6:41-43.
16. Bogdanov V.R. Medico-biological aspects of reproduction of echinococcus multilocularis. Calcium cells as a source of growth potency [In Russian]. *Medicine in Kuzbass.* 2008; 2:40-44.